AAGL 2022

51st GLOBAL CONGRESS ON MIGS

December 1–4, 2022 | Gaylord Rockies Resort and Convention Center | Aurora, Colorado

SYLLABUS

MAST-615: Master's Course in Exposure Retraction and Deep Dissection

SCIENTIFIC PROGRAM CHAIR
ANDREW I. SOKOL, MD

HONORARY CHAIR
CHARLES E. MILLER, MD

PRESIDENT
MAURICIO S. ABRÃO, MD, PHD

Table of Contents

Financial Disclosures 3

Course Program: Course Description, Learning Objectives, Course Outline 4

Laparoscopic Management of Ovarian Remnant
T.T.M. Lee 5

Tackling Oncological and Other Complex Cancer Surgeries
S.P. Puntambekar 9

Challenging Robotic Surgeries
K.E. Patzkowsky 25

Transvaginal Complex Gynecologic Surgery
J.B. Gebhart 32

Single-site vNOTES Routes for Challenging Surgeries
X.Guan 38

Cultural and Linguistic Competency & Implicit Bias 39

Disclosure of Relevant Financial Relationships

As an ACCME accredited provider, AAGL must ensure balance, independence, and objectivity in all CME activities to promote improvements in health care and not proprietary interests of an ineligible company. AAGL controls all decisions related to identification of CME needs, determination of educational objectives, selection and presentation of content, selection of all persons in a position to control content, selection of educational methods, and evaluation of the activity. Course chairs, planning committee members, faculty, authors, moderators, and others in a position to control the content of this activity are required to disclose all financial relationships with ineligible companies. All relevant financial relationships are appropriately mitigated, and peer review is completed by reviewers who have nothing to disclose. Learners can assess the potential for commercial bias when disclosure, mitigation of conflicts of interest, and acknowledgment of commercial support are provided prior to the activity. Informed learners are the final safeguards in assuring that a CME activity is independent from commercial bias. We believe this mechanism contributes to the transparency and accountability of CME.

Asterisk (*) denotes no financial relationships to disclose.

PLANNER DISCLOSURE

The following members of AAGL have been involved in the educational planning and/or review of this course (listed in alphabetical order by last name).

Linda J. Bell, Admin Support, AAGL*
Linda D. Bradley, MD, Medical Director, AAGL*
Erin T. Carey, MD, MSCR
Honorarium: Med IQ
Research Funding: Eximis
Mark W. Dassel, MD*
Linda Michels, Executive Director, AAGL*
Vadim Morozov, MD
Speaker: AbbVie
Consultant: Medtronic, Lumenis
Erinn M. Myers, MD
Speakers Bureau: Intuitive Surgical
Amy J. Park, MD
Speaker: Allergan
Nancy Williams, COO, CME Consultants*
Harold Y. Wu, MD*
Xiaoming Guan, MD, PhD – Speakers Bureau: Applied Medical
Kristin E. Patzkowsky, MD*

SCIENTIFIC PROGRAM COMMITTEE

Andrew I. Sokol, MD - Medical Legal Defense: Johnson & Johnson
Angela Chaudhari, MD - Consultant: Johnson & Johnson
Cara R. King, DO*
Mario Malzoni, MD – Consultant: KARL STORZ
Jessica Opoku-Anane, MD, MS – Consultant: Boston Scientific; Myovant Sciences; AbbVie
Shailesh P. Puntambekar, MD, PHD*
Frank F. Tu, MD, MPH*
Jonathon M. Solnik, MD – Consultant: Olympus; Medtronic; Stockholder: Field Trip Health, Inc.; Felix Health
Linda D. Bradley, MD, Medical Director*
Linda Michels, Executive Director, AAGL*

FACULTY DISCLOSURE

The following have agreed to provide verbal disclosure of their relationships prior to their presentations. They have also agreed to support their presentations and clinical recommendations with the "best available evidence" from medical literature (in alphabetical order by last name). John B. Gebhart, MD, MS – Advisory Board – UroCure; Royalty: Elsevier, UpToDate
Xiaoming Guan, MD, PhD – Speakers Bureau: Applied Medical
Ted T.M. Lee, MD*
Kristin E. Patzkowsky, MD*
Shailesh P. Puntambekar, MD, PhD*

MAST-615: Master's Course in Exposure Retraction and Deep Dissection

Chair: *Xiaoming Guan, MD, PhD, Kristin E. Patzkowsky, MD*

Faculty: *John B. Gebhart, MD, MS, Ted T.M. Lee, MD, Shailesh P. Puntambekar, MD, PhD*

Course Description

Pursuing the perfect surgical skills with optimum surgical routes and platforms for handling challenging surgeries is a fantasy of MIGS surgeons. As we all have known, no see (exposure) with no cut and sailing in uncharted waters (anatomy) with no jumps (deep dissection) are common difficulties faced by surgeons. Exposure retraction and deep dissection are the cornerstone of tackling the situations for the surgeons in the OR, nonetheless with preparation even the worst scenarios ahead can be conquered easing the surgeons' stress. Expert physicians will provide an in-depth discussion on exposure retraction and deep dissection techniques through multitudes of numerous complex cases, including laparoscopic and robotic platform, as well as multiple, single site and transvaginal routes.

The course will also cover novel transvaginal NOTES surgeries for complex cases such as deep infiltrated endometriosis and sacrocolpopexy as alternative route for most minimally invasive route. This course will illustrate the anatomical dissection of uterine transplant, which will bring you multiple views of surgical concepts of exposure and deep dissection through one of most complex surgical types. This course will have a practical focus on teaching tips and tricks for you to apply to your operating room and incorporate them into your pre-operative assessment to ensure your success in handling even the most complex cases.

Learning Objectives

At the conclusion of this course, the participant will be able to: 1) Apply exposure retraction and deep dissection surgical skills on various complex cases in your own practice; 2) Implement a multiplatform technique for even the most complex surgeries; surgeon can absorb the tips and tricks for his most familiar surgical platform; 3) Illustrate the pros and cons of the different routes in challenging surgeries; and 4) Compare how differently specialized surgeons utilize different techniques for the advanced cases.

Course Outline

2:30 pm	Welcome, Introduction and Course Overview	X. Guan/K.E. Patzkowsky
2:35 pm	Laparoscopic Management of Ovarian Remnant	T.T.M. Lee
3:00 pm	Tackling Oncological and Other Complex Cancer Surgeries	S.P. Puntambekar
3:25 pm	Challenging Robotic Surgeries	K.E. Patzkowsky
3:50 pm	Transvaginal Complex Gynecologic Surgery	J.B. Gehart
4:15 pm	Single-site and vNOTES Routes for Challenging Surgeries	X. Guan
4:40 pm	Questions & Answers	All Faculty
5:00 pm	Adjourn	

Ovarian Remnant: Diagnosis, Prevention and Management

Ted Lee, M.D.
Director, Minimally Invasive Gynecologic Surgery
Magee Womens Hospital

Conflict of Interest Disclosure

None

Objectives

- Describe risk factor and presenting symptoms of ovarian remnant.
- Explain the key diagnostic modalities for ovarian remnant.
- Recognize the surgical risks associated with surgical management of ovarian remnant.
- Use anatomic approach in the prevention and management of ovarian remnant

---

Ovarian Remnant : Definition

- Retention of ovarian tissue with prior documentation of prior salpingoophrectomy.

Common Risk Factors

- Endometriosis
- Previous surgeries
- PID

Ovarian Remnant: Initial Clinical Presentations

Studies	Mayo 2005	Mayo 2007	Magee 2011
Pain	48% (89/186)	90 % (18/20)	96 % (29/30)
Mass	57% (105/186)	10 % (2/20)	4% (1/30)

Kho RM, Magrina JF, Magtibay PM. Pathologic findings and outcomes of a minimally invasive approach to ovarian remnant syndrome. FertilSteril. 2007;87

Magtibay PM, Nyholm JL, Hernandez JL, Podraz KC. Ovarian remnant syndrome. Am J Obstet Gynecol. 2005;193

Arden D. Lee TM Laparoscopic Excision of Ovarian Remnants: A Retrospective Cohort Study with Long-Term Follow-Up. J Min Inv Gyne 2011, 18 (2)

Ovarian Remnant: Symptoms

Studies	Mayo 2005	Magee 2011
Pelvic Pain	66%	96% (29/30)
LLQ pain		55.2% (16/29)
RLQ pain		27.6% (8/29)
Lower abdominal pain		17.2% (5/29)
Dyspareunia	26%	56.7% (17/29)
Dyschezia	6%	36.7% (11/29)
Dysuria	7%	20% (6/29)

Magtibay PM, Nyholm JL, Hernandez JL, Podraz KC. Ovarian remnant syndrome. Am J Obstet Gynecol. 2005;193

Arden D. Lee TM Laparoscopic Excision of Ovarian Remnants: A Retrospective Cohort Study with Long-Term Follow-Up. J Min Inv Gyne 2011, 18 (2),

Ovarian Remnant: Patient Characteristics

Studies	Mayo 2005	Nezhat 2005	Mayo 2007	Magee 2011
Age (years)	37.6	38.7	48	38.6
Previous Laparotomy	1.4	2	2.7	2.5
Previous Laparoscopy	0.77	2	1.4	1.9
Previous Surgical Attempts	35%	15.6%	0%	17%

Kho RM, Magrina JF, Magtibay PM. Pathologic findings and outcomes of a minimally invasive approach to ovarian remnant syndrome. FertilSteril. 2007;87

Magtibay PM, Nyholm JL, Hernandez JL, Podraz KC. Ovarian remnant syndrome. Am J Obstet Gynecol. 2005;193

Arden D. Lee TM Laparoscopic Excision of Ovarian Remnants: A Retrospective Cohort Study with Long-Term Follow-Up. J Min Inv Gyne 2011, 18 (2)

Nezhat C, Kearney S, Malik S, Nezhat C, Nezhat F. Laparoscopic management of ovarian remnant. Fertil Steril. 2005;83

Ovarian Remnant after Unilateral Salpingoophrectomy

Studies	Nezhat 2005	Magee 2011
	30% (19/64)	20% (6/30)

Arden D. Lee TM Laparoscopic Excision of Ovarian Remnants: A Retrospective Cohort Study with Long-Term Follow-Up. J Min Inv Gyne 2011, 18 (2),

Nezhat C, Kearney S, Malik S, Nezhat C, Nezhat F. Laparoscopic management of ovarian remnant. Fertil Steril. 2005;83

Ovarian Remnant: Diagnosis

Studies	Mayo 2005	Nezhat 2005	Magee 2011
Ultrasound	93%	80.4% (US &CT)	89.6%
Premenopausal FSH (<30 IU/dL)	69%	NA	59.1%
Premenopausal E2 (>35 pg/mL)	63%	NA	70.6%

Magtibay PM, Nyholm JL, Hernandez JL, Podraz KC. Ovarian remnant syndrome. Am J Obstet Gynecol. 2005;193

Arden D. Lee TM Laparoscopic Excision of Ovarian Remnants: A Retrospective Cohort Study with Long-Term Follow-Up. J Min Inv Gyne 2011, 18 (2),

Nezhat C, Kearney S, Malik S, Nezhat C, Nezhat F. Laparoscopic management of ovarian remnant. Fertil Steril. 2005;83

Location of Ovarian Remnant

Location	Magee 2011
Left	60% (18/30)
Right	23.3% (7/30)
Bilateral	16.7% (5/30)

Arden D. Lee TM Laparoscopic Excision of Ovarian Remnants: A Retrospective Cohort Study with Long-Term Follow-Up. J Min Inv Gyne 2011, 18 (2),

Location of Ovarian Remnant

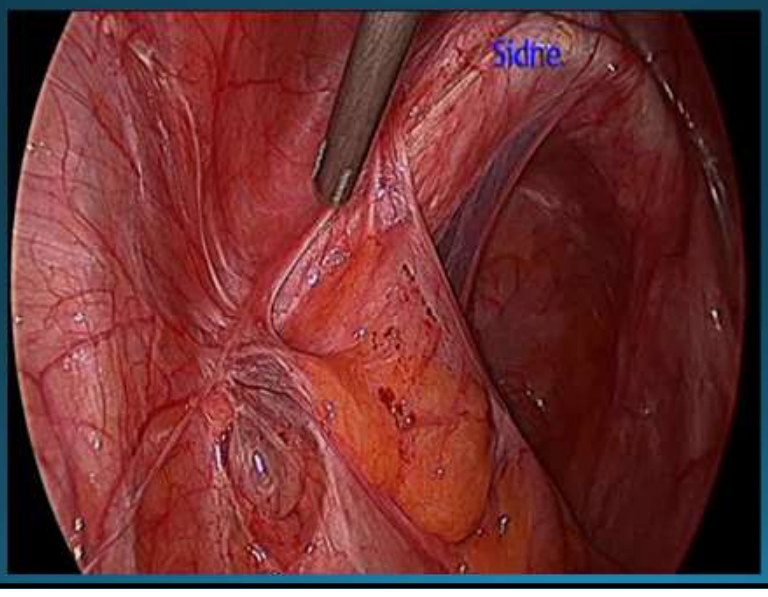

Complexities of Ovarian Remnant Surgeries

Studies	Nezhat 2005	Magee 2011
Enterolysis	90.6 % (58/64)	90.0% (27/30)
Uretolysis	73.4% (47/64)	93.3 % (28/30)

Arden D. Lee TM Laparoscopic Excision of Ovarian Remnants: A Retrospective Cohort Study with Long-Term Follow-Up. J Min Inv Gyne 2011, 18 (2),

Nezhat C, Kearney S, Malik S, Nezhat C, Nezhat F. Laparoscopic management of ovarian remnant. Fertil Steril. 2005;83

Intraop Complications/Complexities of ORS Surgeries

Studies	Mayo 2005	Nezhat 2005	Magee 2011
Bowel injury with primary repair	5%		13.3% (4/30)
Bowle injury with primary resection		7.8% (5/64)	10% (3/30)
Bladder Injury with primary repair	2%	1.6%(1/64)	6.7%(2/30)
Ureteral injury/repair	1%	1.6 (1/64)	0
Transfusion	12%	0	0
Conversion	NA	3.1% (2/64)	0
Recurrences/ Persistence	1%	12.5% (8/64)	0

Post-op Complications of ORS Surgeries

Studies	Mayo 2005	Nezhat 2005	Magee 2011
Vesicovaginal Fistula	0	1.6% (1/64)	0
Ureteral Obstruction	2%	0	0
DVT or PE	2%	0	0
Ileus or partial SBO	8%	0	0
Transfusion	12%	0	0
Conversion	NA	3.1% (2/64)	0
Recurrences/ Persistence	1%	12.5% (8/64)	0
Reoperation for Pain or Remnant	9%	7.8 %(5/64)	6.6% (2/30)

Preventing Ovarian Remnant

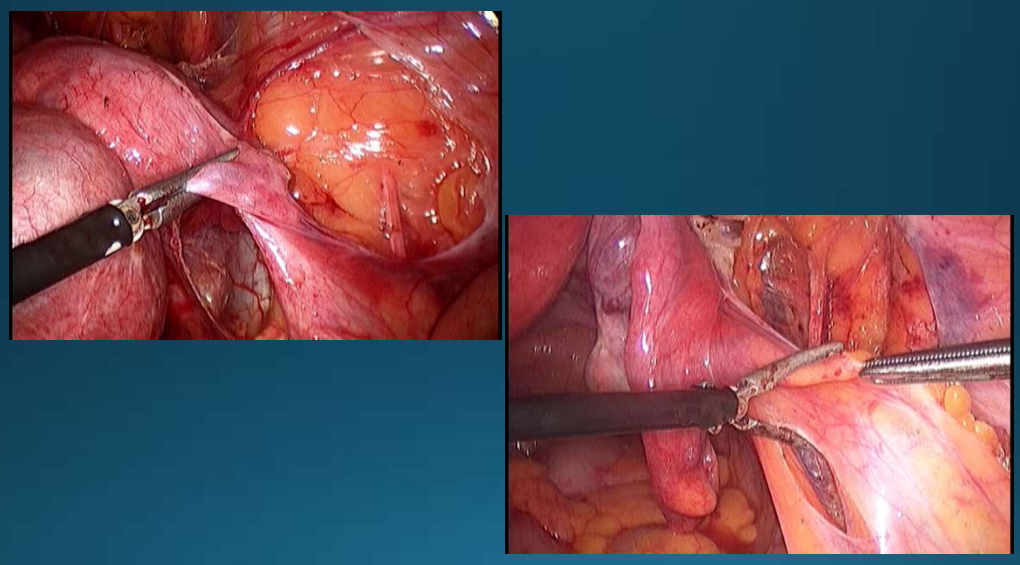

Preventing Ovarian Remnant

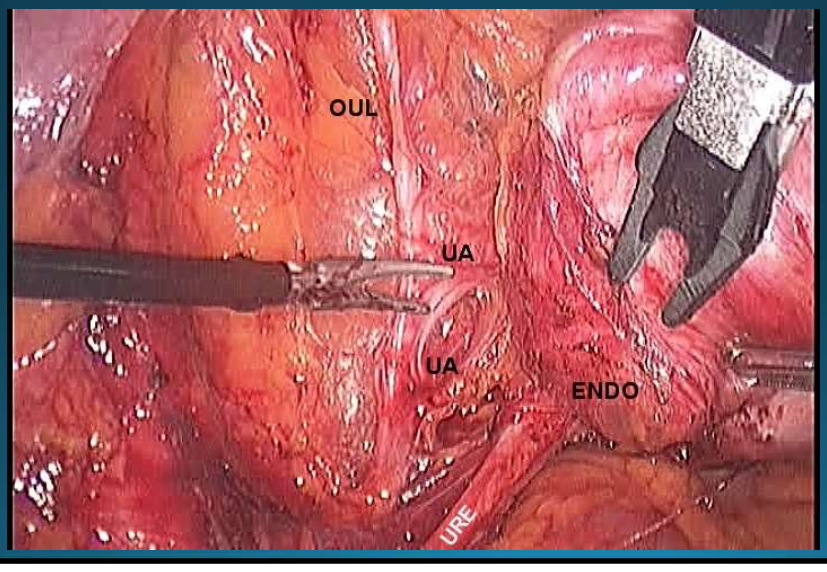

Ovarian Remnant Prevention

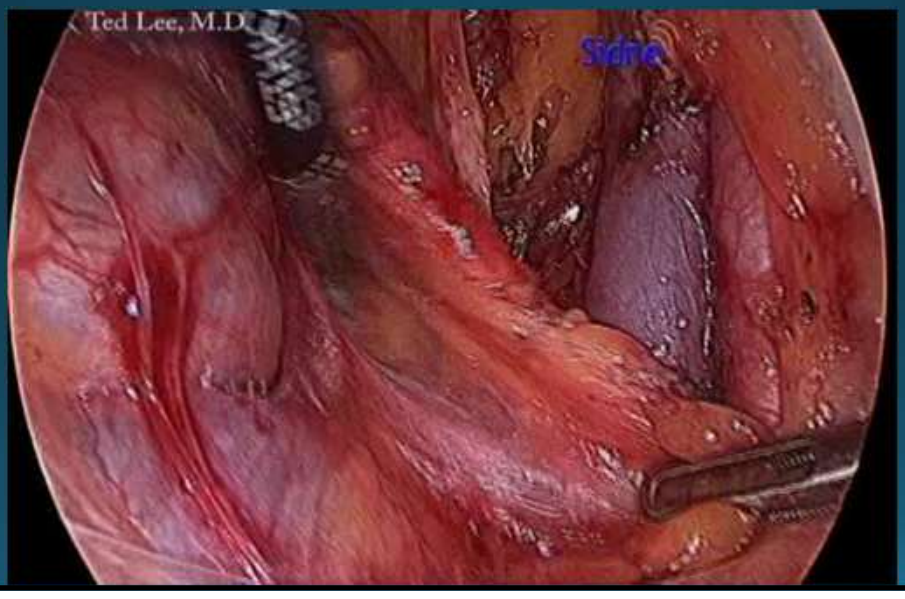

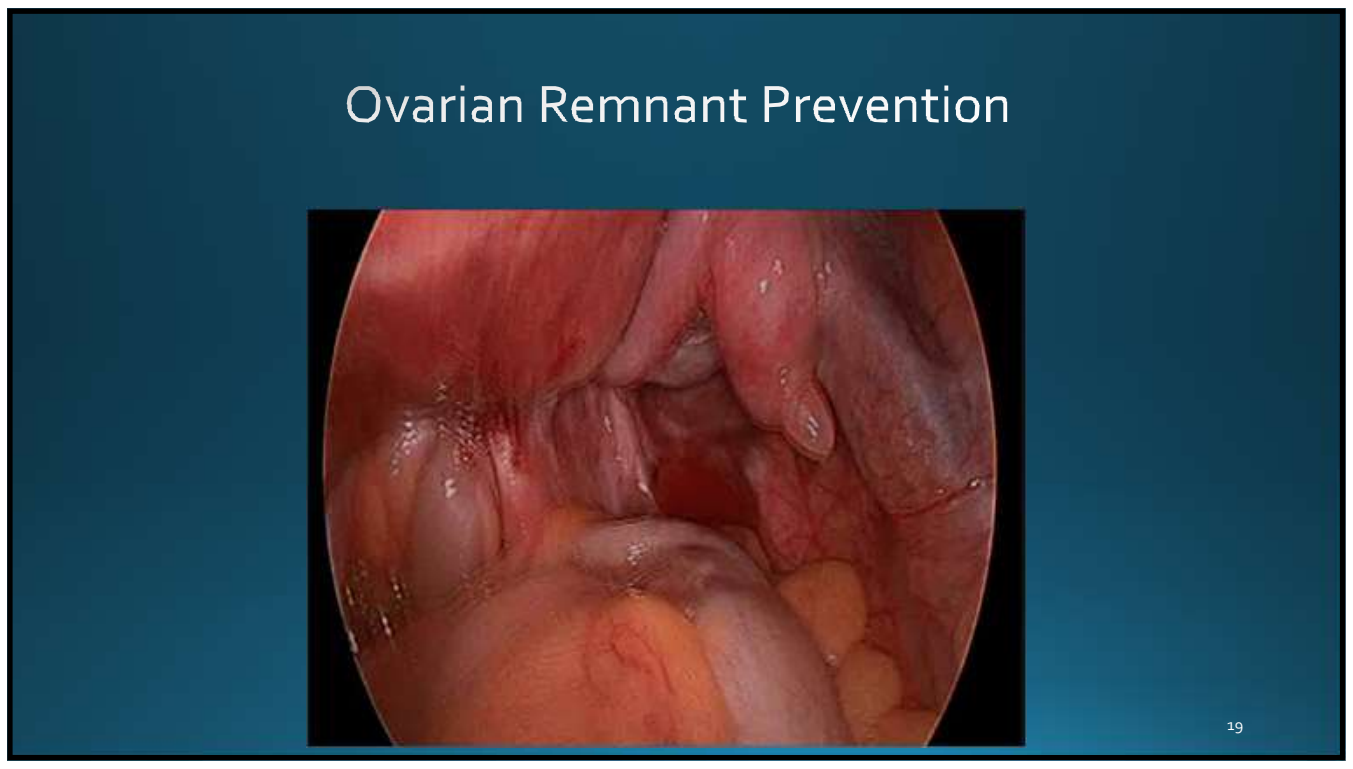

Ovarian Remnant Prevention

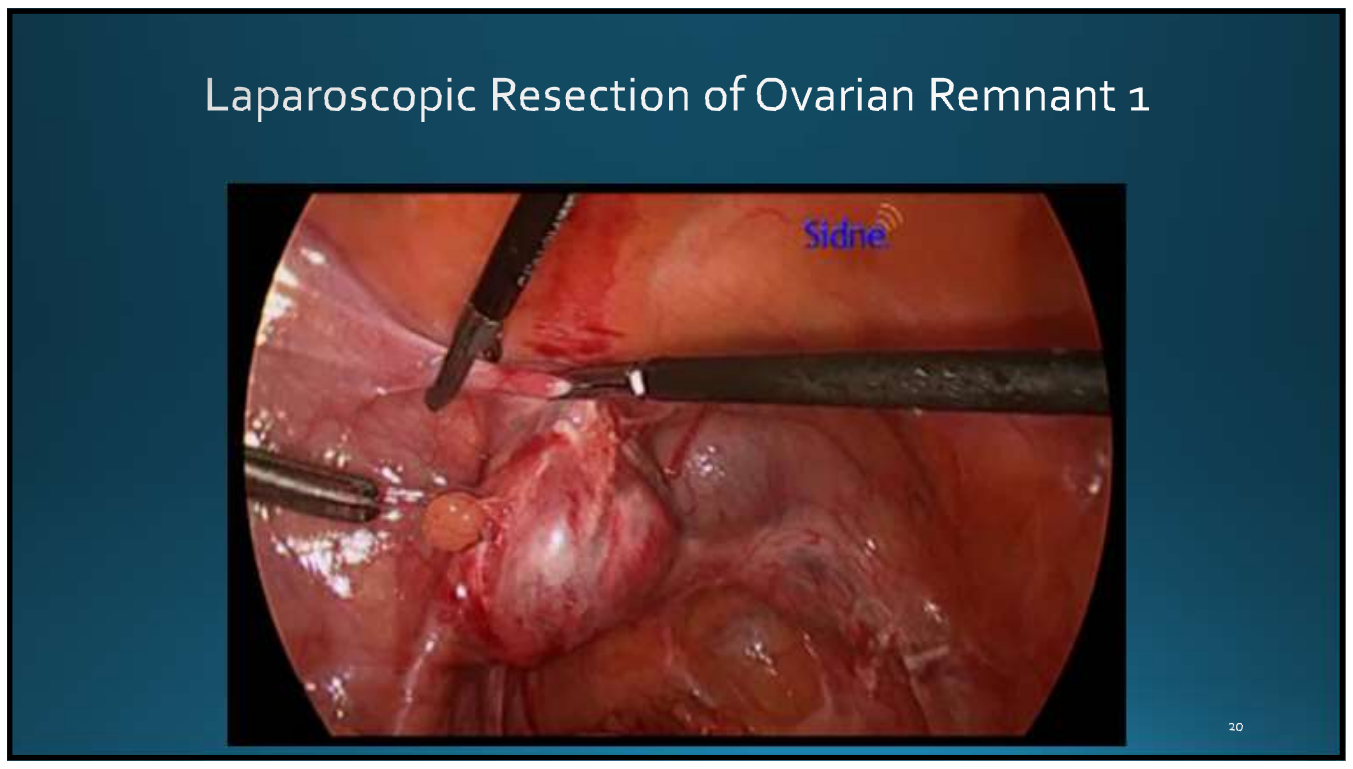

Laparoscopic Resection of Ovarian Remnant 1

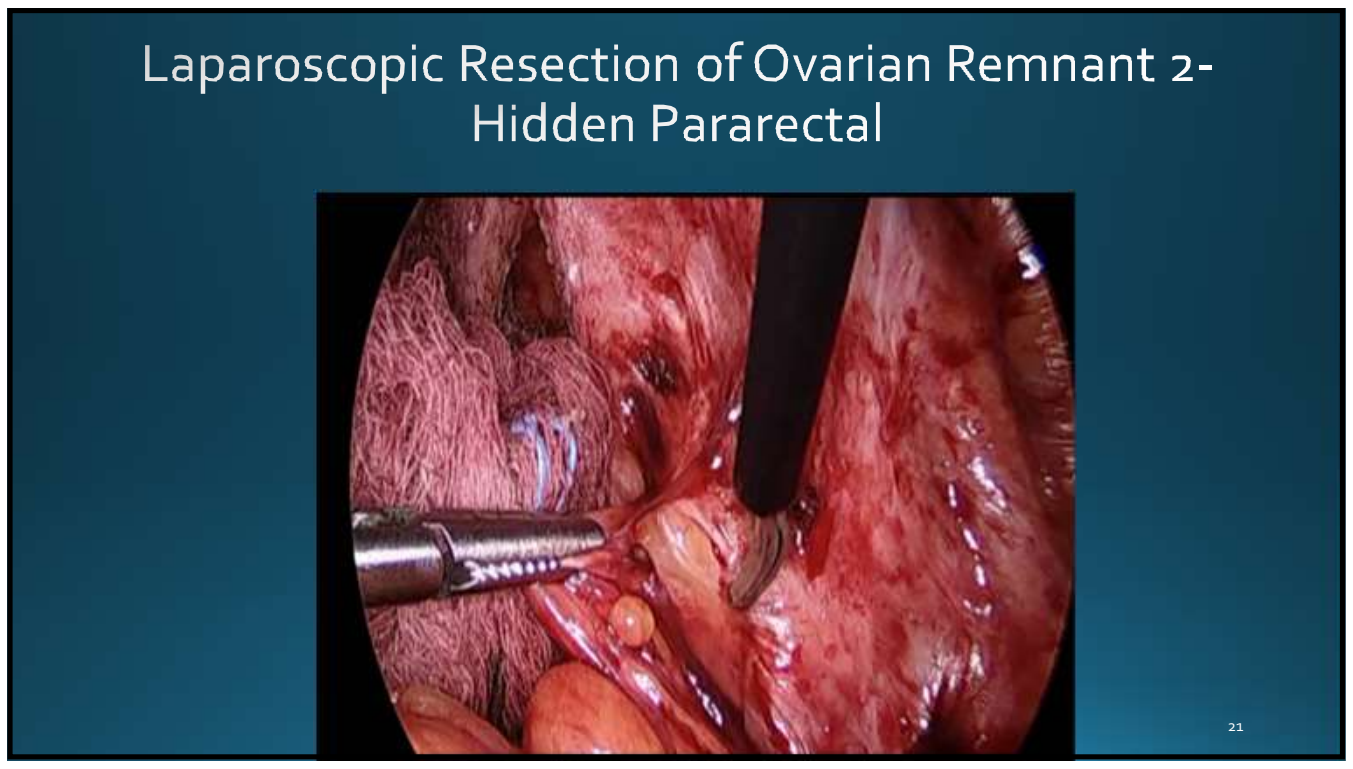

Laparoscopic Resection of Ovarian Remnant 2- Hidden Pararectal

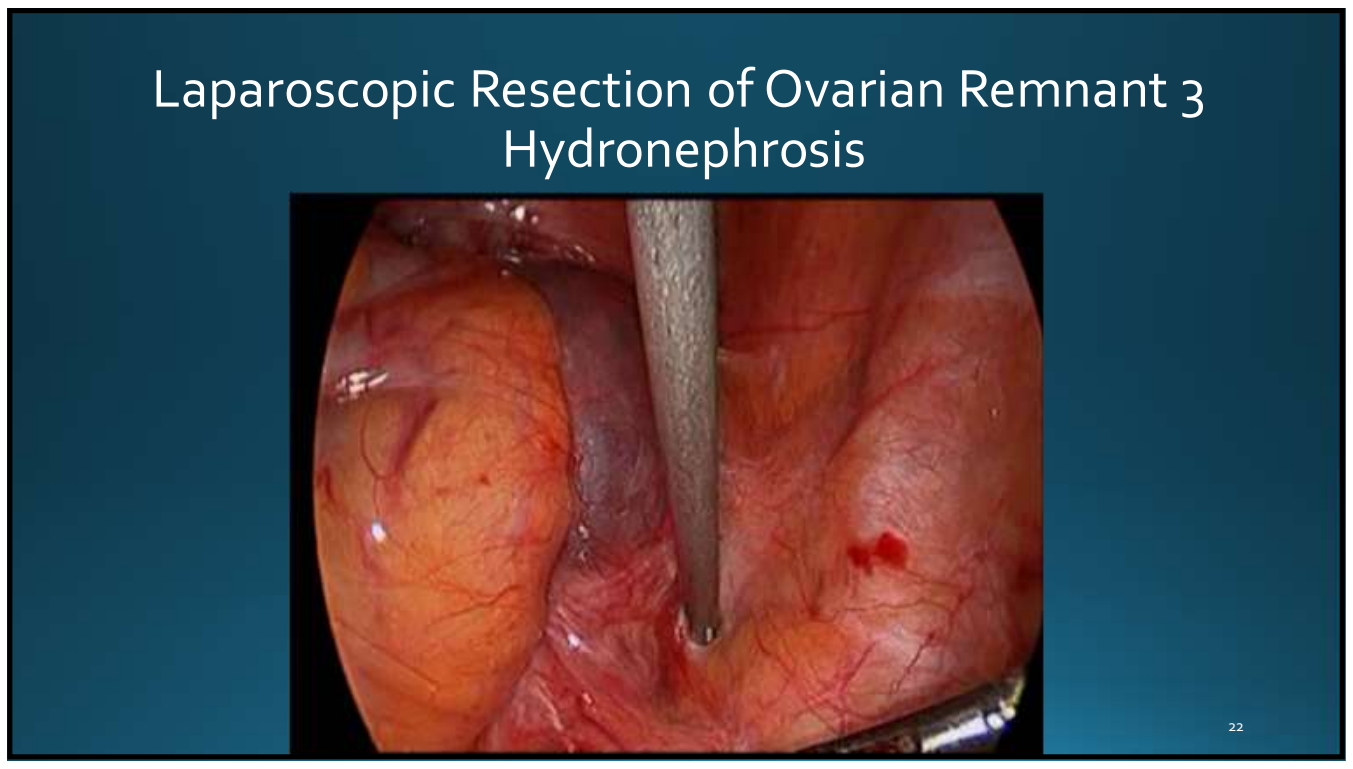

Laparoscopic Resection of Ovarian Remnant 3 Hydronephrosis

References

- Magtibay PM, Nyholm JL, Hernandez JL, Podraz KC. Ovarian remnant syndrome. Am J Obstet Gynecol. 2005; 193(6):2062-6.
- Arden D, Lee T. Laparoscopic excision of ovarian remnants: retrospective cohort study with long-term follow-up. J Minim Invasive Gynecol. 2011;18:194–199.
- Nezhat C, Kearney S, Malik S, Nezhat C, Nezhat F. Laparoscopic management of ovarian remnant. Fertil Steril. 2005;83:973–978
- Kho RM, Magrina JF, Magtibay PM. Pathologic findings and outcomes of a minimally invasive approach to ovarian remnant syndrome. FertilSteril. 2007;87(5):1005-9

Conclusion

- High index suspicion is essential for the diagnosis of ovarian remnant in patients with high risk factors.
- Imaging and/or premenopausal hormones will detect close to 100% of ovarian remnant.
- Ovarian remnant is a surgically challenging condition even in the best of hands.
- Risk of visceral injury and its associated repair is high. Discussion of the specific risks should be carefully documented in the inform consent process.
- Adherence to the anatomic approach to salpingoophrectomy will minimize the risk of ovarian remnant.
- Laparoscopic resection of ovarian remnant is safe and feasible in the majority of cases.

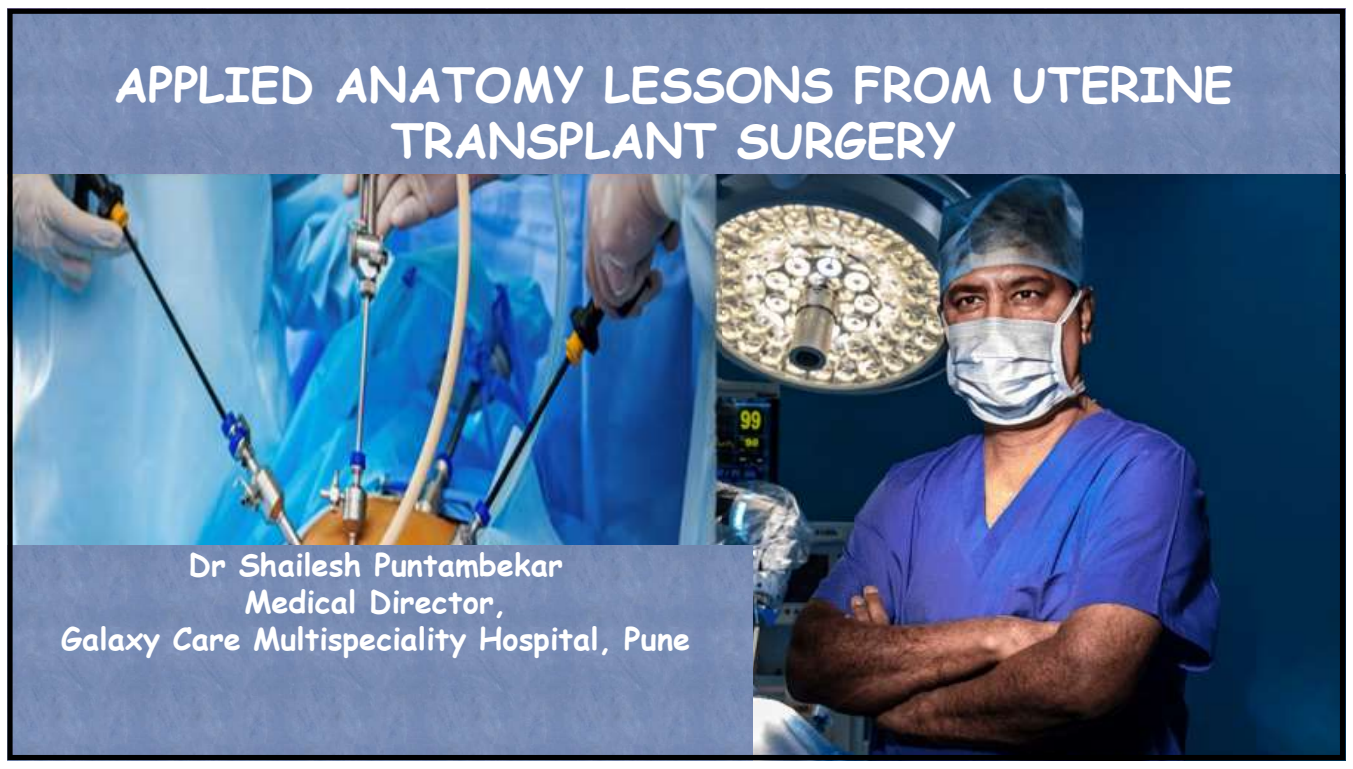

APPLIED ANATOMY LESSONS FROM UTERINE TRANSPLANT SURGERY

Dr Shailesh Puntambekar
Medical Director,
Galaxy Care Multispeciality Hospital, Pune



Hello Everyone

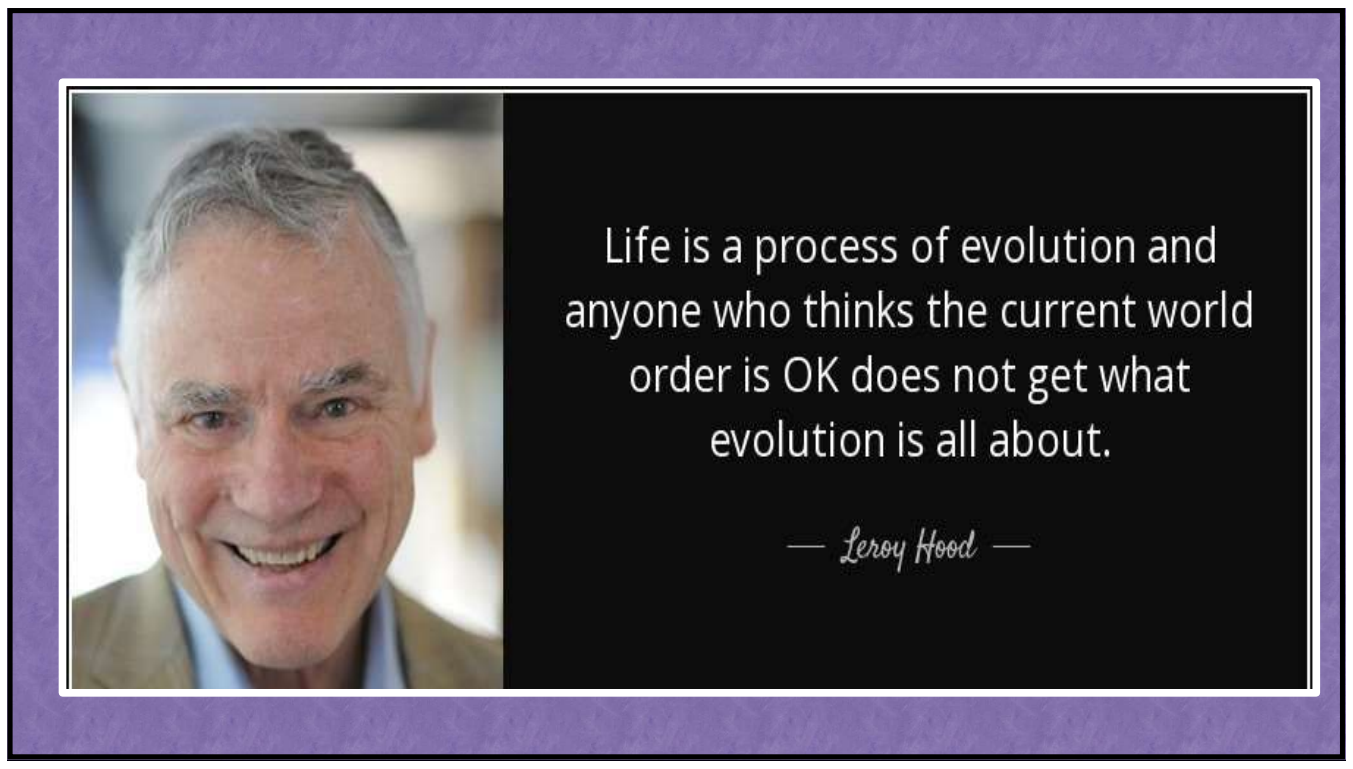

> Life is a process of evolution and anyone who thinks the current world order is OK does not get what evolution is all about.
>
> — Leroy Hood —

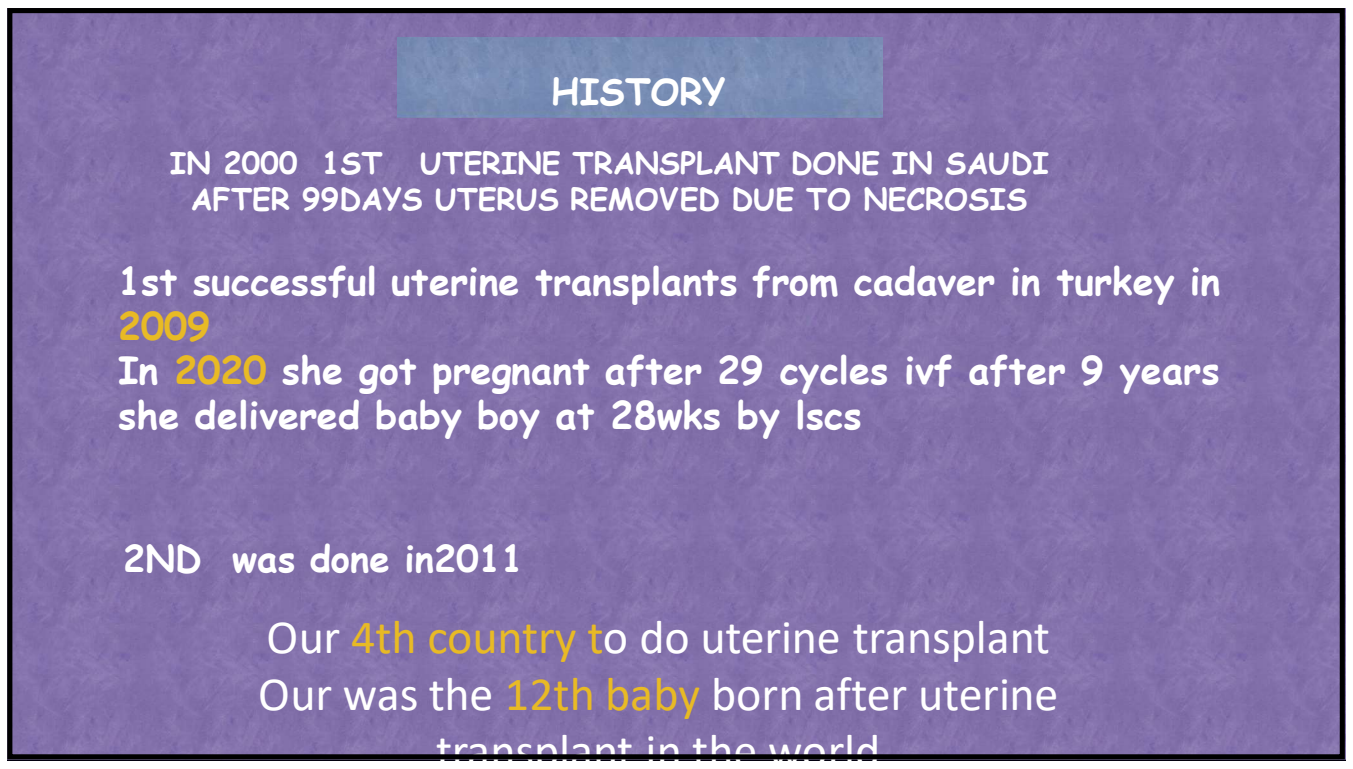

HISTORY

IN 2000 1ST UTERINE TRANSPLANT DONE IN SAUDI
AFTER 99DAYS UTERUS REMOVED DUE TO NECROSIS

1st successful uterine transplants from cadaver in turkey in 2009
In 2020 she got pregnant after 29 cycles ivf after 9 years she delivered baby boy at 28wks by lscs

2ND was done in2011

Our 4th country to do uterine transplant
Our was the 12th baby born after uterine transplant in the world

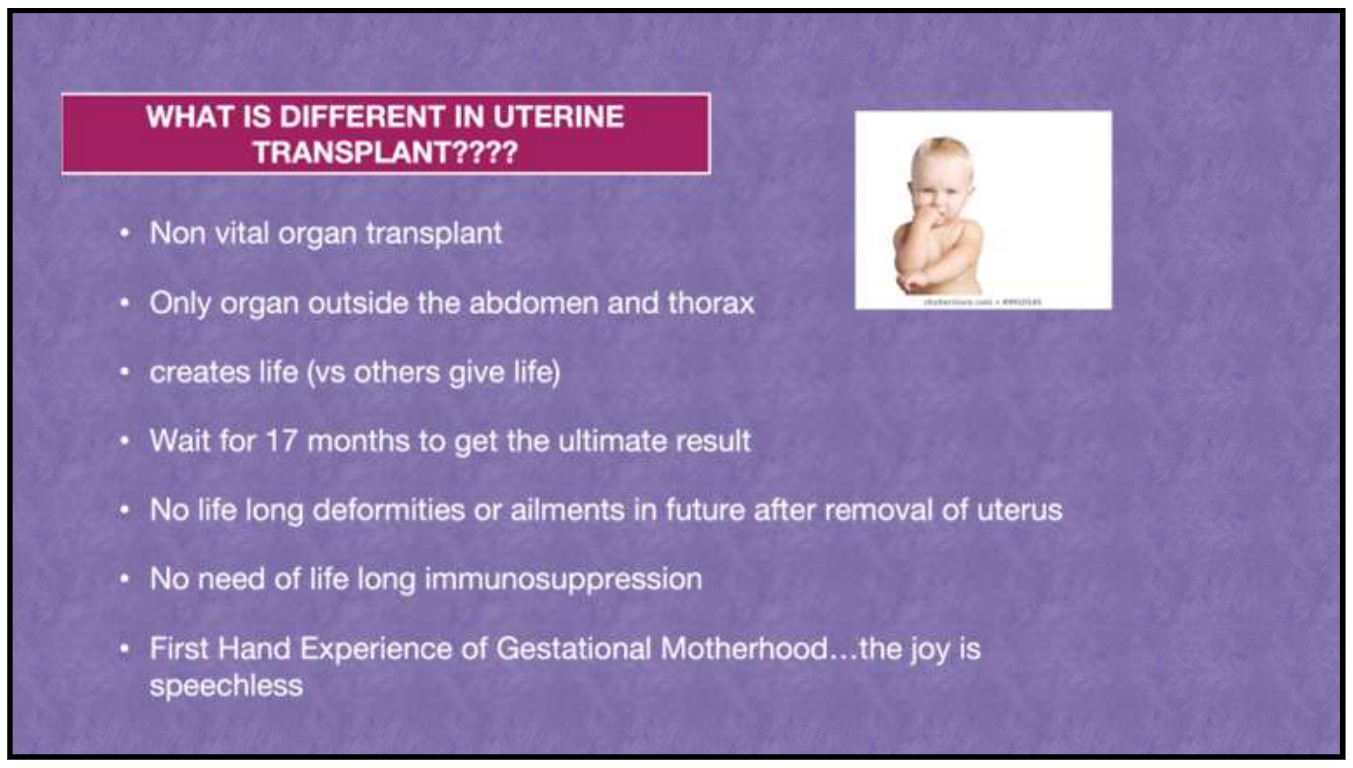

WHAT IS DIFFERENT IN UTERINE TRANSPLANT????

- Non vital organ transplant
- Only organ outside the abdomen and thorax
- creates life (vs others give life)
- Wait for 17 months to get the ultimate result
- No life long deformities or ailments in future after removal of uterus
- No need of life long immunosuppression
- First Hand Experience of Gestational Motherhood…the joy is speechless

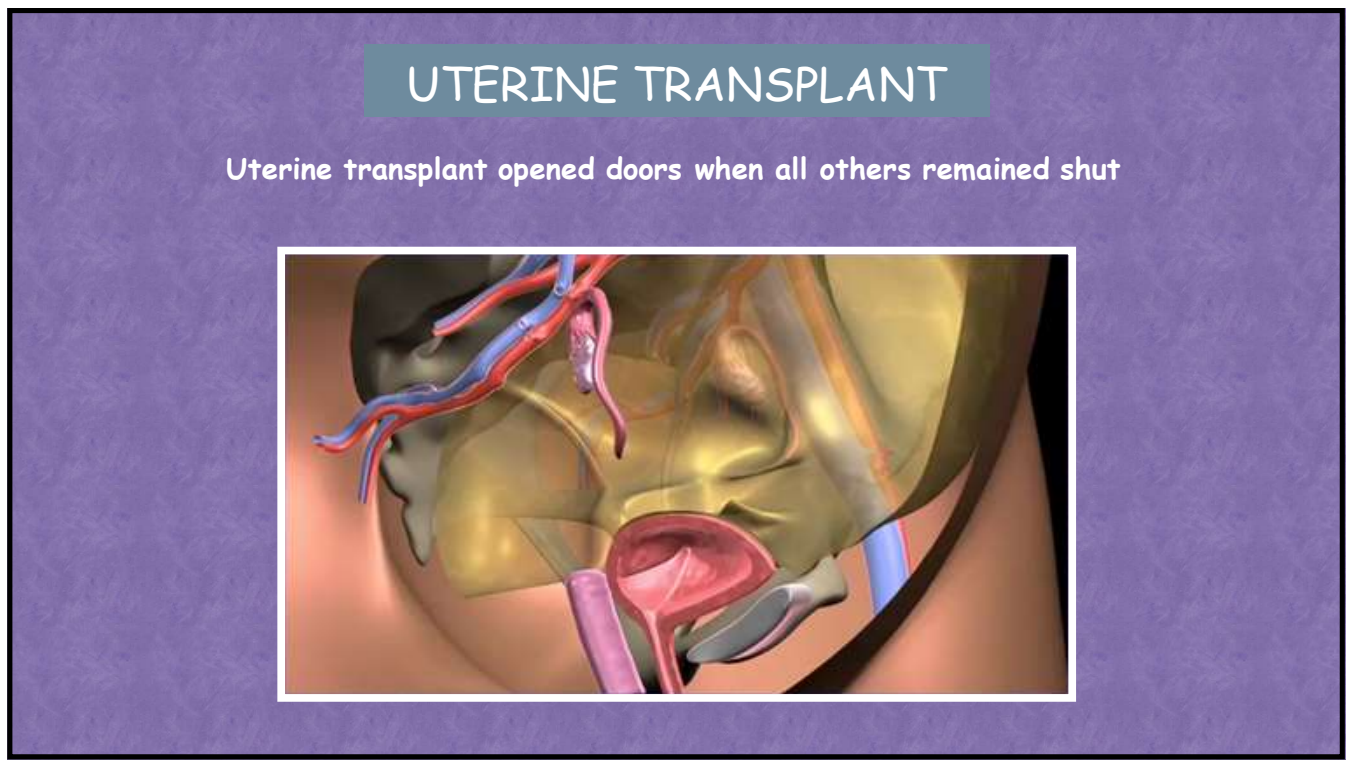

UTERINE TRANSPLANT

Uterine transplant opened doors when all others remained shut

FIGO COMMITTEE FOR ETHICAL ASPECTS OF HUMAN REPRODUCTION & WOMAN HEALTH

Deemed Uterine Transplant Unethical given the lack of data on safety & efficacy

RITERIA for ethical feasibility of Uterine Transplant " is an attempt to

MONTREAL CRITERIA FOR SELECTION

-SELECTION CRITERIA FOR DONOR

- SELECTION CRITERIA FOR RECIPENT
- SELECTION OF YOUR "TRANSPLANT TEAM"

PREPARATION

Today's Preparation...
Tomorrow's SUCCESS!

INSPIRED FROM

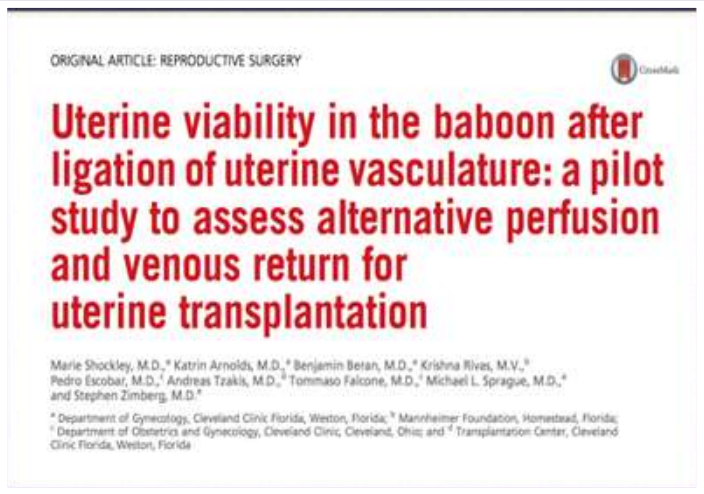
ORIGINAL ARTICLE: REPRODUCTIVE SURGERY

Uterine viability in the baboon after ligation of uterine vasculature: a pilot study to assess alternative perfusion and venous return for uterine transplantation

Marie Shockley, M.D.,[a] Katrin Arnolds, M.D.,[a] Benjamin Beran, M.D.,[a] Krishna Rivas, M.V.,[b] Pedro Escobar, M.D.,[c] Andreas Tzakis, M.D.,[d] Tommaso Falcone, M.D.,[c] Michael L. Sprague, M.D.,[a] and Stephen Zimberg, M.D.[a]

[a] Department of Gynecology, Cleveland Clinic Florida, Weston, Florida; [b] Mannheimer Foundation, Homestead, Florida; [c] Department of Obstetrics and Gynecology, Cleveland Clinic, Cleveland, Ohio; and [d] Transplantation Center, Cleveland Clinic Florida, Weston, Florida

INSPIRED FROM

LAPAROSCOPIC RADICAL TRACHELECTOMY

WE ASKED

Why ONLY uterine vessels, why Ovarian vessels not considered ??

Why 14 hrs were spent for such a surgery ??

Why put a patient through 14 hrs of Anaesthesia ??

What About the PROLONGED ISCHEMIA TIME ?

Why Can't it be done by Laparoscopy ??

Can It be done in India ??

A Right Approach Towards Uterine Transplant Can Be Achieved Through CADAVERIC DISSECTION

Dr. Shailesh Puntambekar demonstrating pelvic dissection

A big Thank You to Marcello and team!

OUR TEAM

- Chief Operating Surgeon
- Vascular Surgeon
- Plastic Surgeon
- Gynaecologists
- High Risk Obstetricians
- Transplant Physicians
- IVF Specialists
- Neonatologist
- Assisting Surgeons
- Transplant Pyschiatrist
- Transplant Counsellor
- Transplant Co-ordinator

STEPS

Infundibulopelvic (IP) ligament was skeletonized upto the brim. Ovarian artery and vein were dissected till their entry into the IP ligament.

STEP

paracectal and paravesical spaces were dissected upto the Levator Ani muscle

Pararectal Space

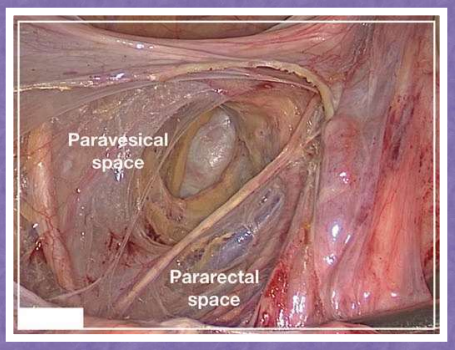
Paravesical space
Pararectal space

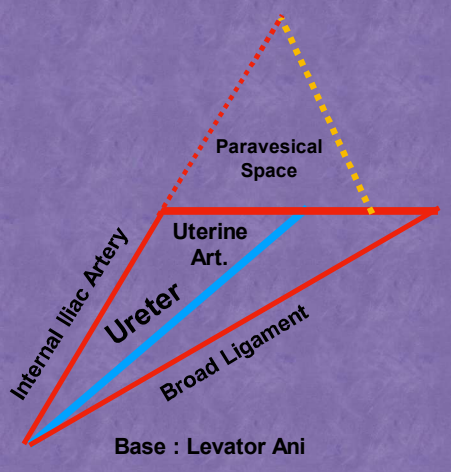
Paravesical Space
Uterine Art.
Internal Iliac Artery
Ureter
Broad Ligament

Base : Levator Ani

Ureter Divides Pararectal Space into

Medial - Okabayashi

Lateral - Latzko

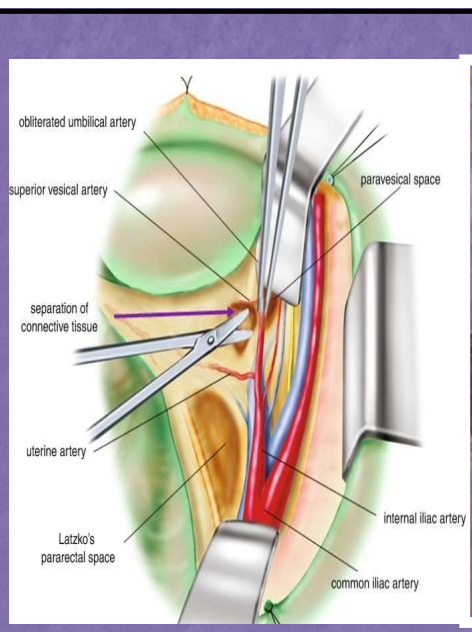
obliterated umbilical artery
superior vesical artery
separation of connective tissue
uterine artery
Latzko's pararectal space
paravesical space
internal iliac artery
common iliac artery

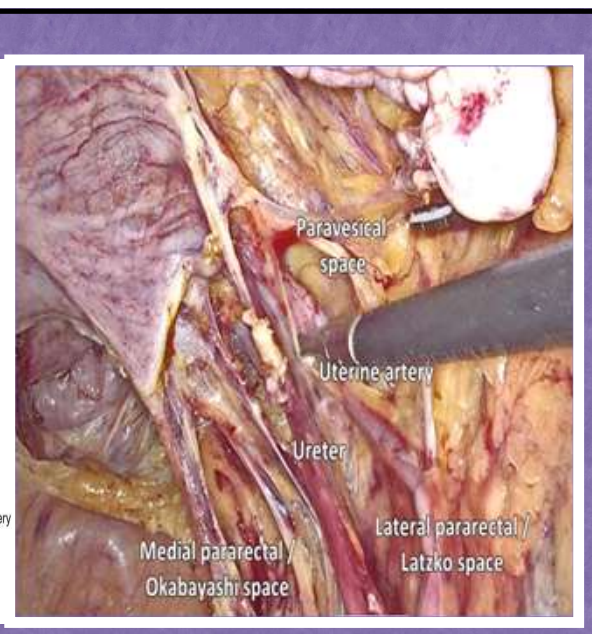
Paravesical space
Uterine artery
Ureter
Medial pararectal/ Okabayashi space
Lateral pararectal/ Latzko space

PARARECTAL SPACE

Medial Approach

Lateral approach

Entering the Space following separation of Posterior fascia of Transverse Cervical Ligament and Int. Iliac vessel Sheath from the main body

---

Medial Pararectal Space	Lateral Pararectal Space
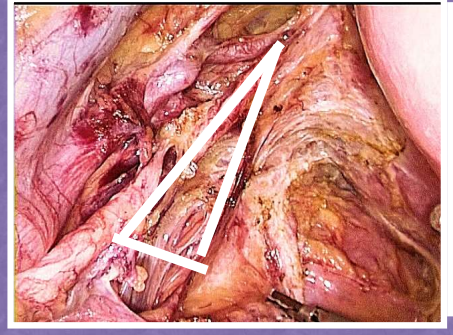	
Contains Superior Hypogastric Plexus and Hypogastric nerves	Contains the pelvic splanchnic nerves and uterine artery Best place to clamp Uterine Artery
Essential in Nerve-Sparing Radical Hysterectomy	Essential in Any Hysterectomy

---

Paravesical Space

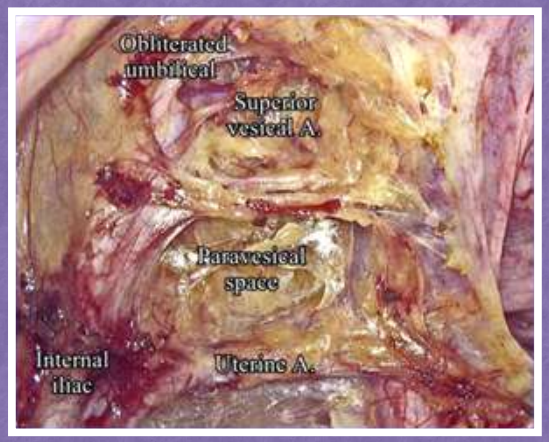
Obliterated umbilical
Superior vesical A.
Paravesical space
Internal iliac
Uterine A.

Content:
Obturator Neurovascular bundle
Lymphatics
BEWARE OF CORONA MORTIS

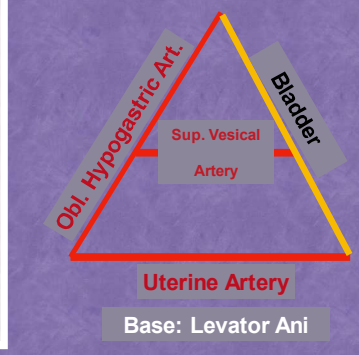
Obl. Hypogastric Art.
Bladder
Sup. Vesical Artery
Uterine Artery
Base: Levator Ani

Uses
Best Access to Lateral pelvic Wall for Optimal Oncological Clearance & Lymph Node dissection

---

Paravesical Space

STEP 3

The pouch of Douglas was dissected. Rectovaginal space was dissected upto the Levator Ani

KNOWLEDGE OF PELVIC AVASCULAR SPACES IS MUST

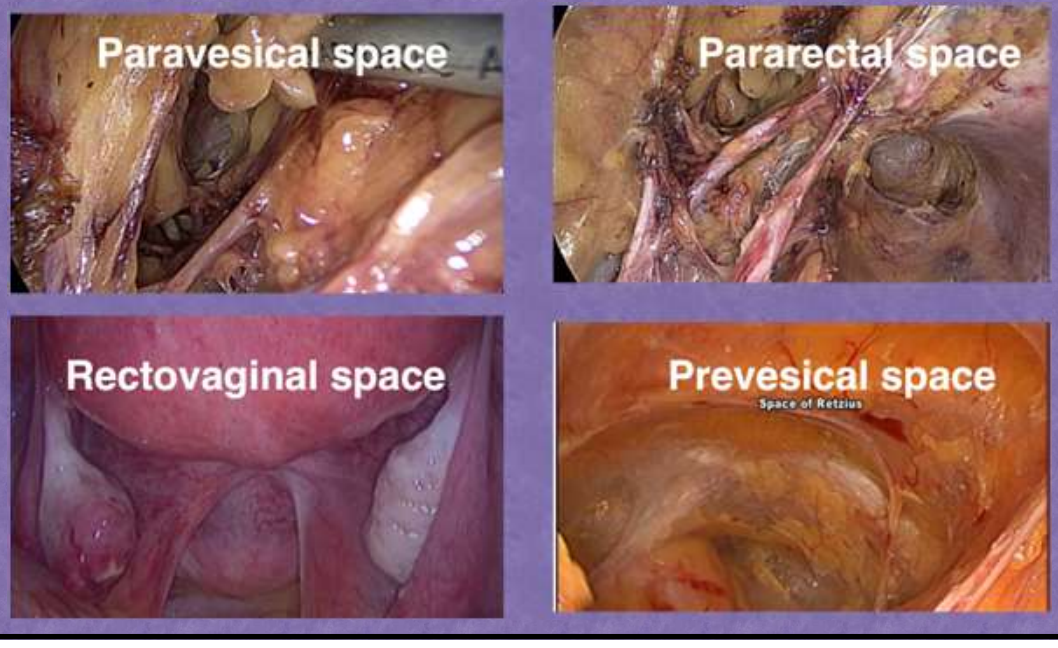
Paravesical space
Pararectal space
Rectovaginal space
Prevesical space
Space of Retzius

STEP

The key step in
this surgery is the ureteric dissection

The Uterine artery and vein have arborisation and small branches around the ureter were carefully separated, ligated or clipped. Thus, the left ureter was lateralized, totally separated from all around and completely denuded

TRACING OF URETER

If there is venous bleeding then the ureter is lifted anteriorly and bleeding to be controlled and if its areterial bleeding it come from the top

URETERIC TUNNEL DISSECTION

UNDERSTANDING OF ANTERIOR PARAMETRIUM HELPS

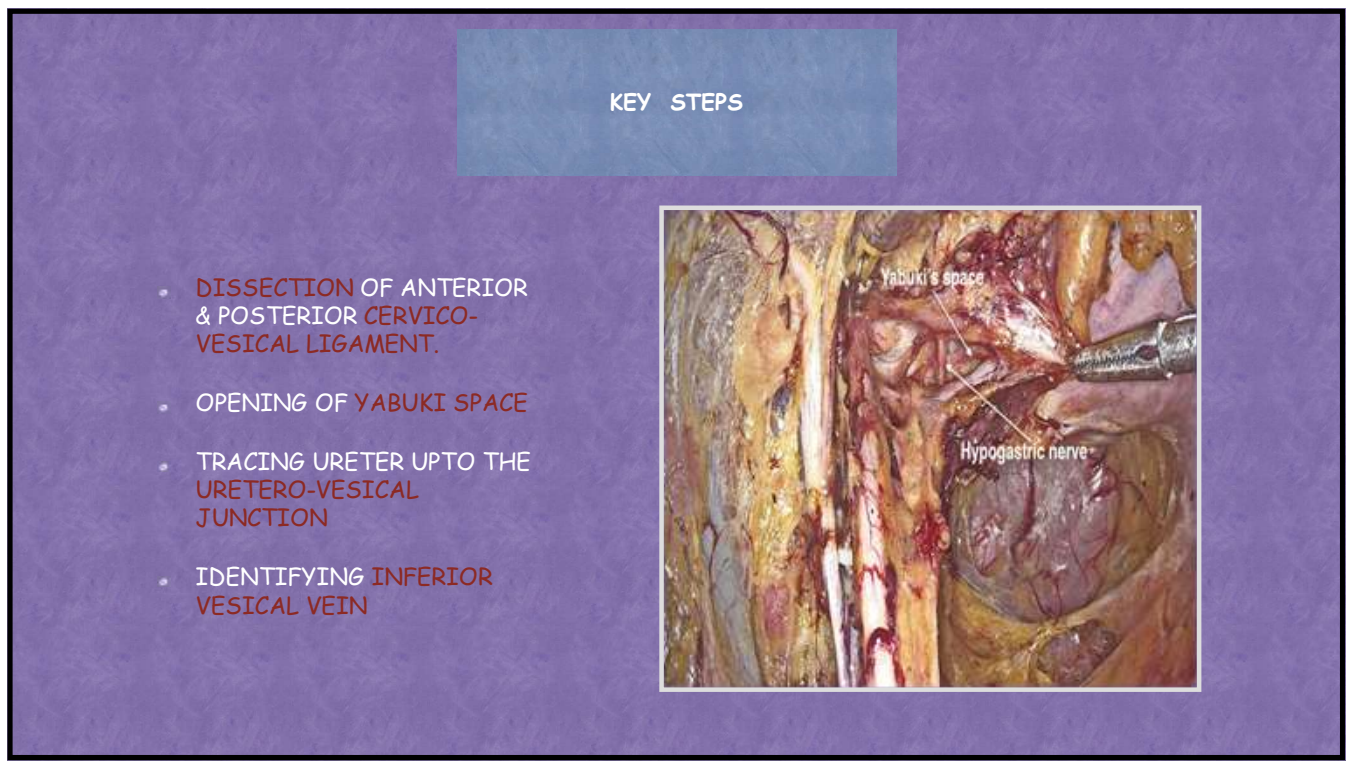

KEY STEPS

- DISSECTION OF ANTERIOR & POSTERIOR CERVICO-VESICAL LIGAMENT.
- OPENING OF YABUKI SPACE
- TRACING URETER UPTO THE URETERO-VESICAL JUNCTION
- IDENTIFYING INFERIOR VESICAL VEIN

Yabuki's space
Hypogastric nerve

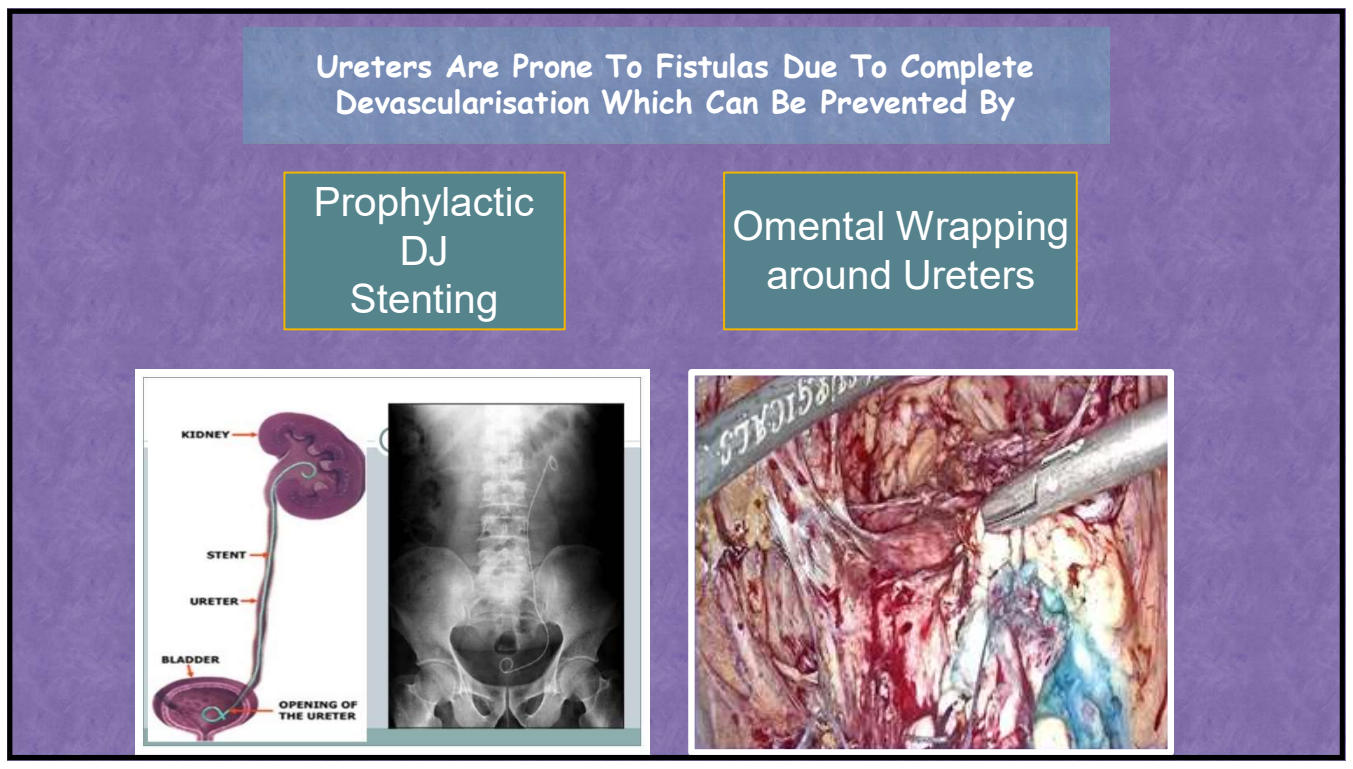

Ureters Are Prone To Fistulas Due To Complete Devascularisation Which Can Be Prevented By

Prophylactic DJ Stenting

Omental Wrapping around Ureters

KIDNEY
STENT
URETER
BLADDER
OPENING OF THE URETER

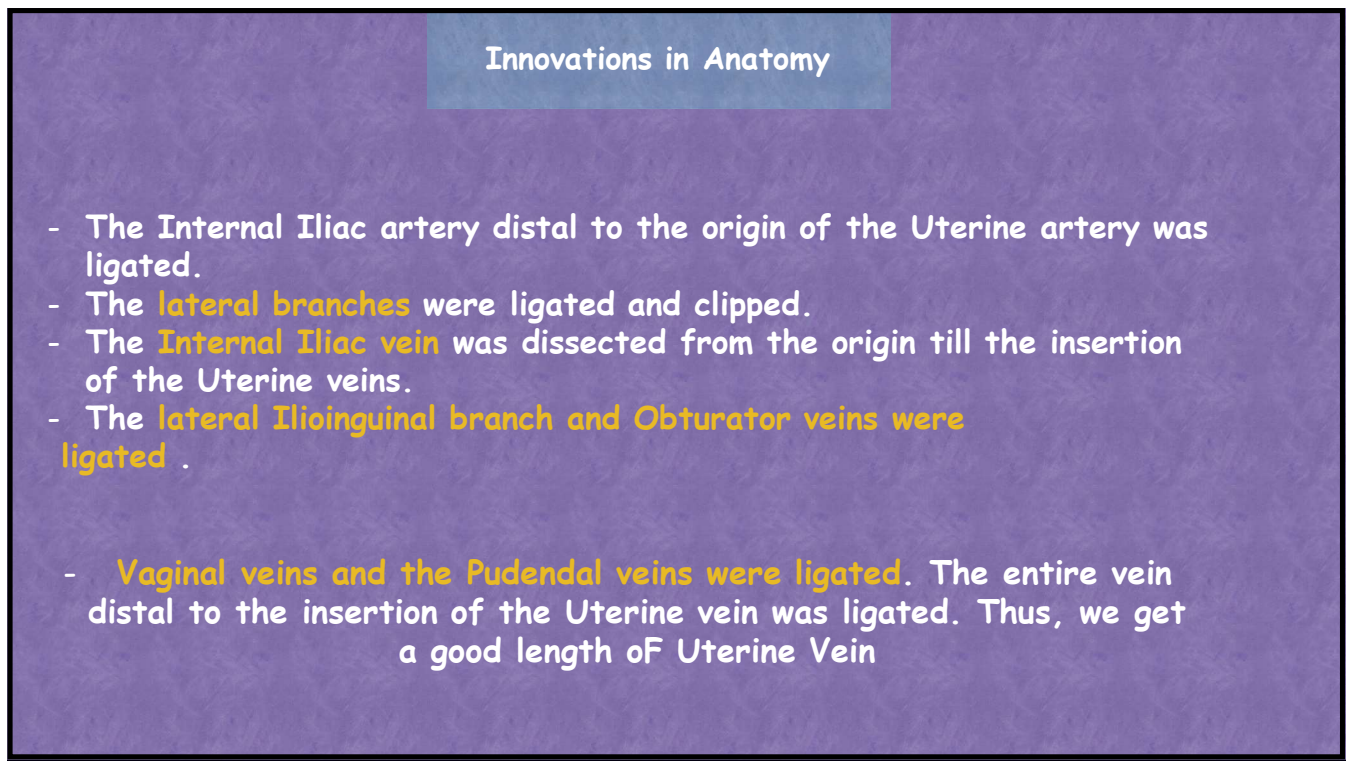

Innovations in Anatomy

- The Internal Iliac artery distal to the origin of the Uterine artery was ligated.
- The lateral branches were ligated and clipped.
- The Internal Iliac vein was dissected from the origin till the insertion of the Uterine veins.
- The lateral Ilioinguinal branch and Obturator veins were ligated .

- Vaginal veins and the Pudendal veins were ligated. The entire vein distal to the insertion of the Uterine vein was ligated. Thus, we get a good length oF Uterine Vein

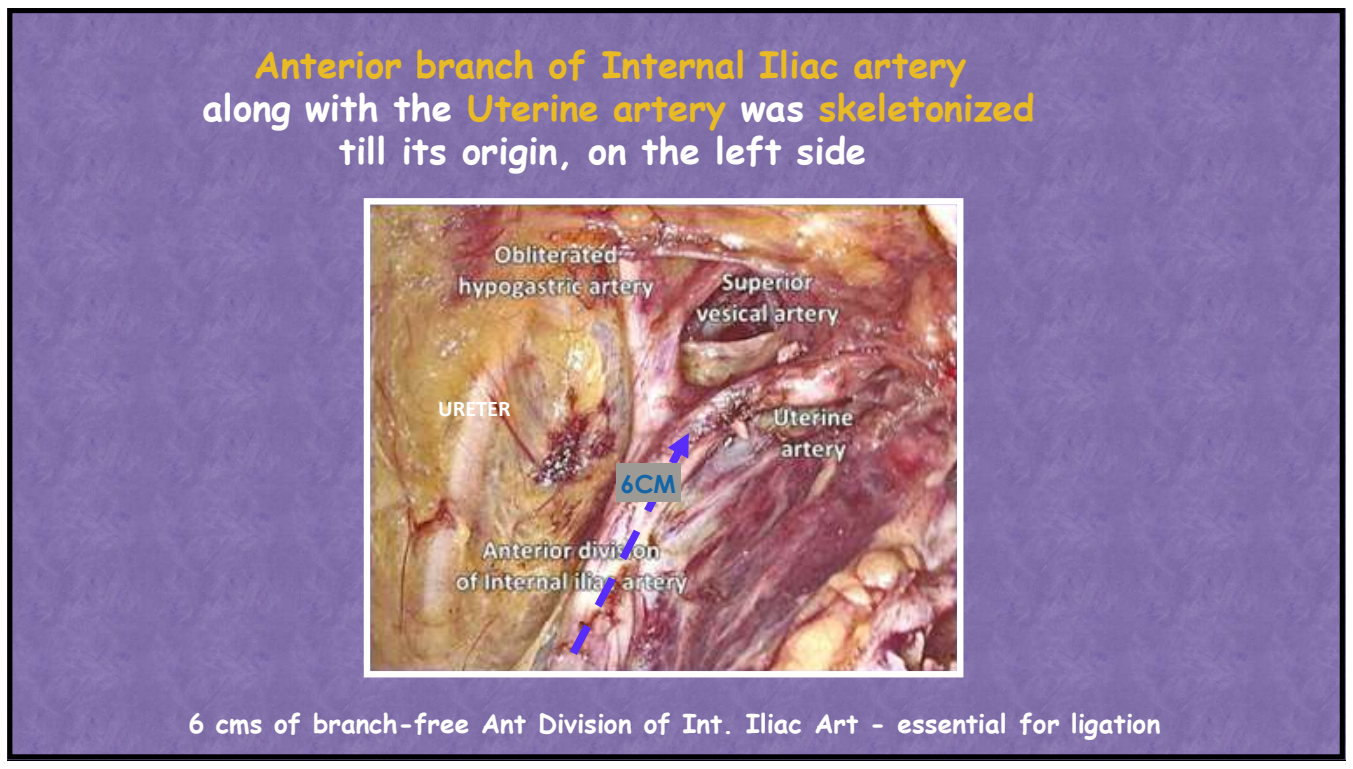

Anterior branch of Internal Iliac artery along with the Uterine artery was skeletonized till its origin, on the left side

Obliterated hypogastric artery
Superior vesical artery
URETER
Uterine artery
6CM
Anterior division of Internal iliac artery

6 cms of branch-free Ant Division of Int. Iliac Art - essential for ligation

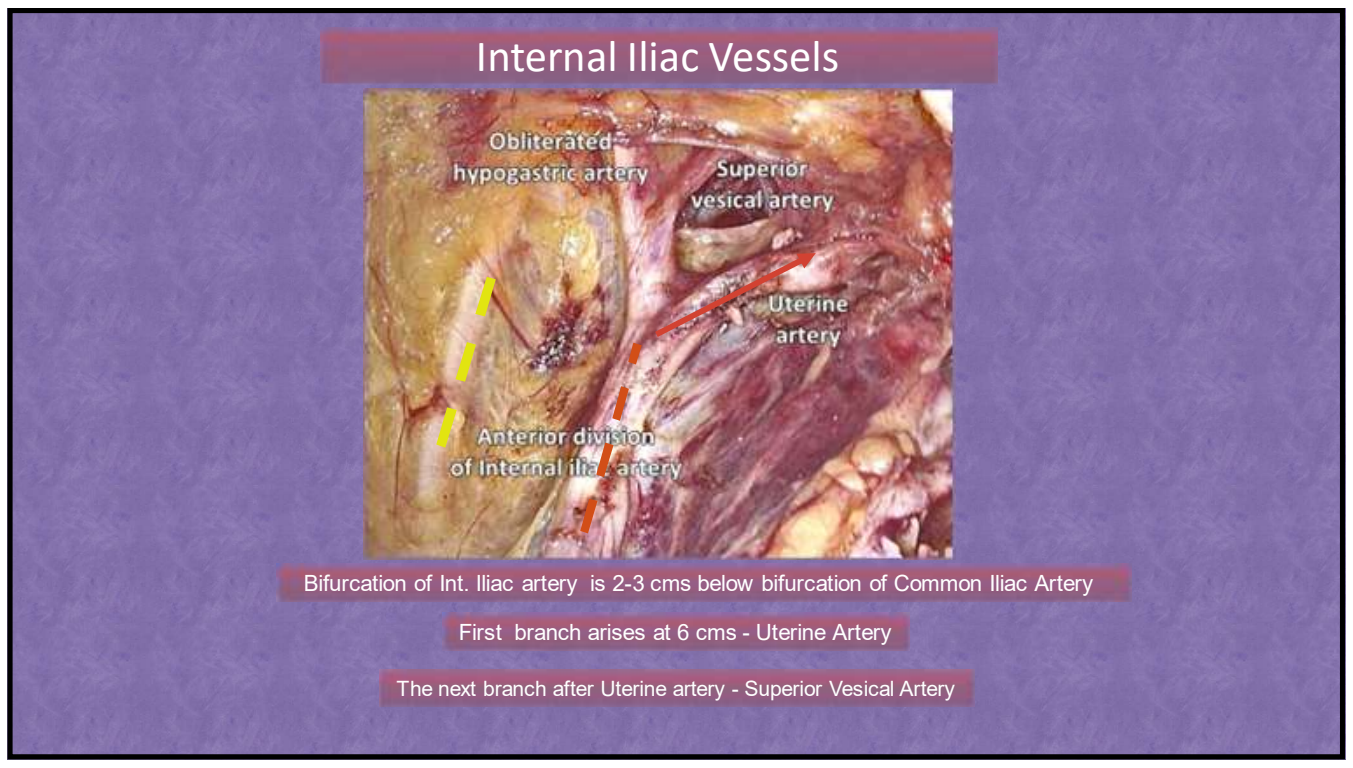

Internal Iliac Vessels

Obliterated hypogastric artery
Superior vesical artery
Uterine artery
Anterior division of Internal iliac artery

Bifurcation of Int. Iliac artery is 2-3 cms below bifurcation of Common Iliac Artery

First branch arises at 6 cms - Uterine Artery

The next branch after Uterine artery - Superior Vesical Artery

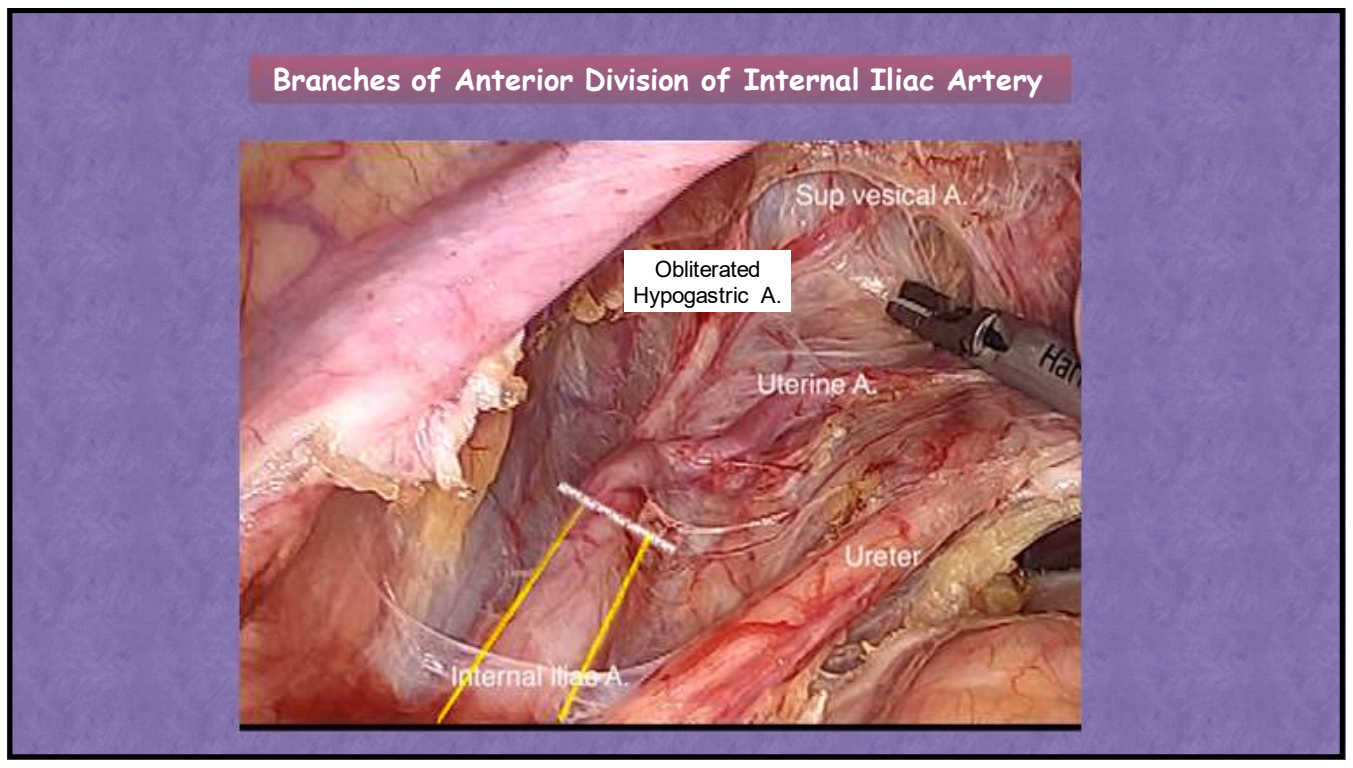

Branches of Anterior Division of Internal Iliac Artery

Sup vesical A.
Obliterated Hypogastric A.
Uterine A.
Ureter
Internal iliac A.

Innovations in Anatomy

Internal Iliac veins are very deeply seated difficult to harvest,very time consuming and too much morbidity to the donor

The Finer Details Of Uterine Artery Was Examined And Dissected

UTERINE ARTERY BRANCHES CLIPPING

ABANDON ONE SIDE OVARIAN VEIN AND ARTERY

ARTERY AND VEIN

The uterus can
survive with
ONE UTERINE
ARTERY
and ONE OVARIAN
VEIN

Advantages of Abandoning Uterine Vein

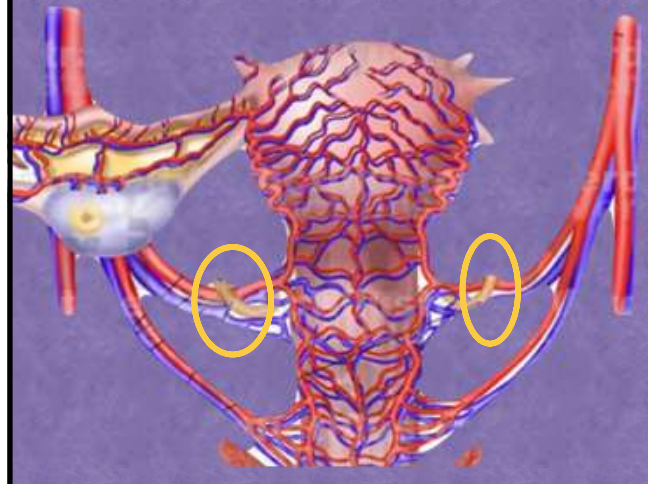

No traction of lower uterus while formation of supports

Easy Suturing of Mackenrodt's ligament

Least morbid procedure

Innovations In Vascular Anastomosis

Left Side

Right Side

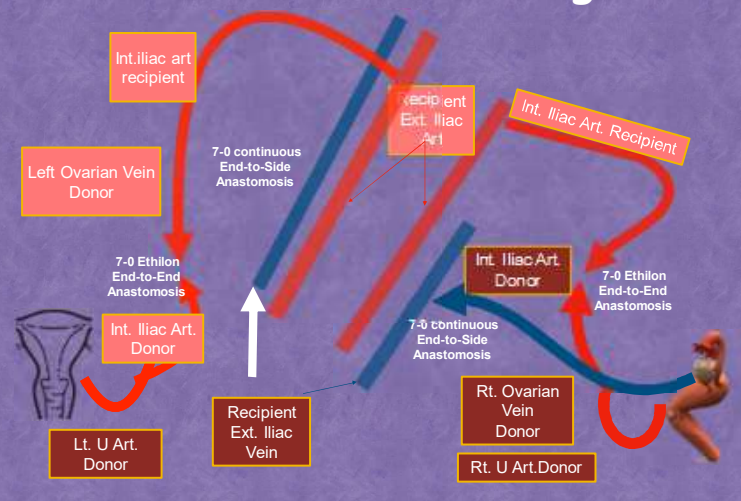

Int.iliac art recipient

Left Ovarian Vein Donor

7-0 continuous End-to-Side Anastomosis

Recipient Ext. Iliac Art

Int. Iliac Art. Recipient

7-0 Ethilon End-to-End Anastomosis

Int. Iliac Art. Donor

Int. Iliac Art. Donor

7-0 Ethilon End-to-End Anastomosis

7-0 continuous End-to-Side Anastomosis

Recipient Ext. Iliac Vein

Rt. Ovarian Vein Donor

Lt. U Art. Donor

Rt. U Art.Donor

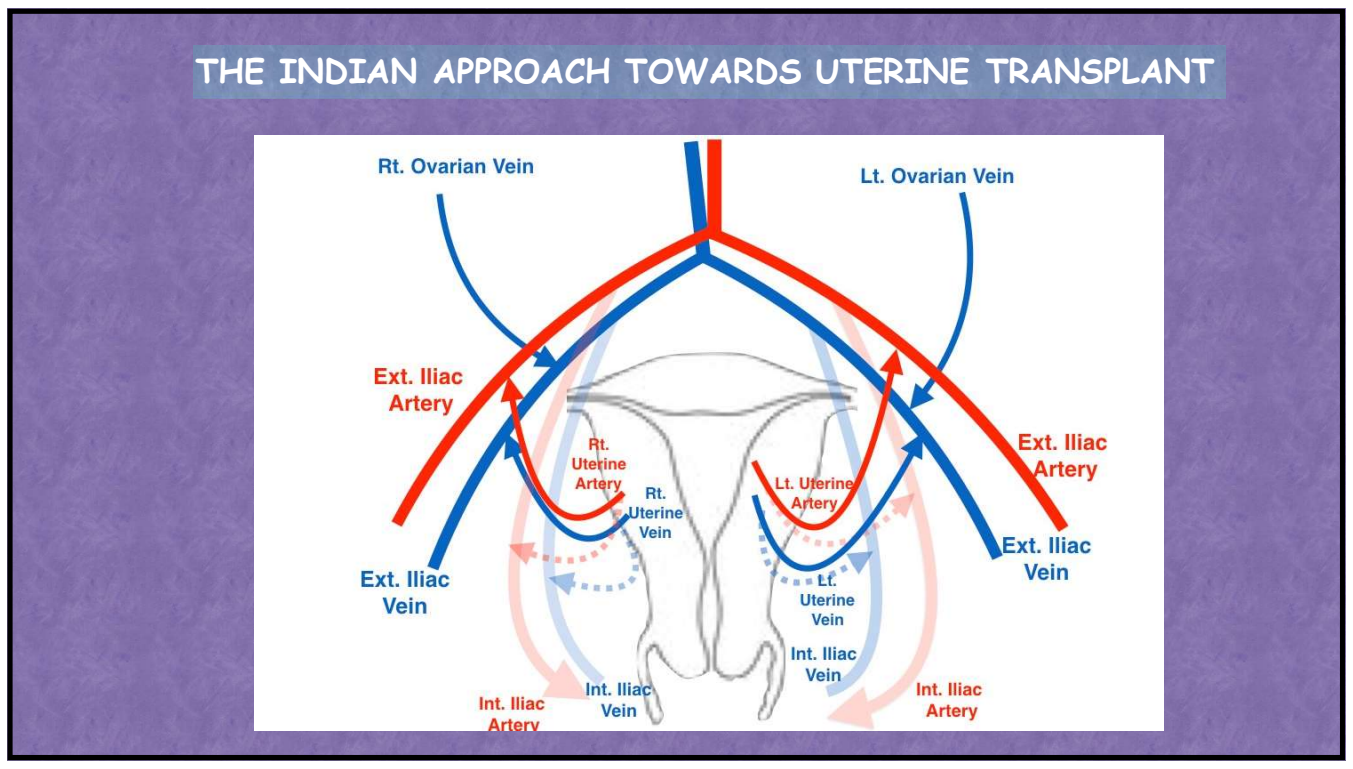

THE INDIAN APPROACH TOWARDS UTERINE TRANSPLANT

Rt. Ovarian Vein
Lt. Ovarian Vein
Ext. Iliac Artery
Ext. Iliac Artery
Rt. Uterine Artery
Rt. Uterine Vein
Lt. Uterine Artery
Ext. Iliac Vein
Ext. Iliac Vein
Lt. Uterine Vein
Int. Iliac Vein
Int. Iliac Artery
Int. Iliac Vein
Int. Iliac Artery

Numerous Trial Bench Surgeries in routine Hysterectomy Specimens Enabled Us To Unlock The Secrete

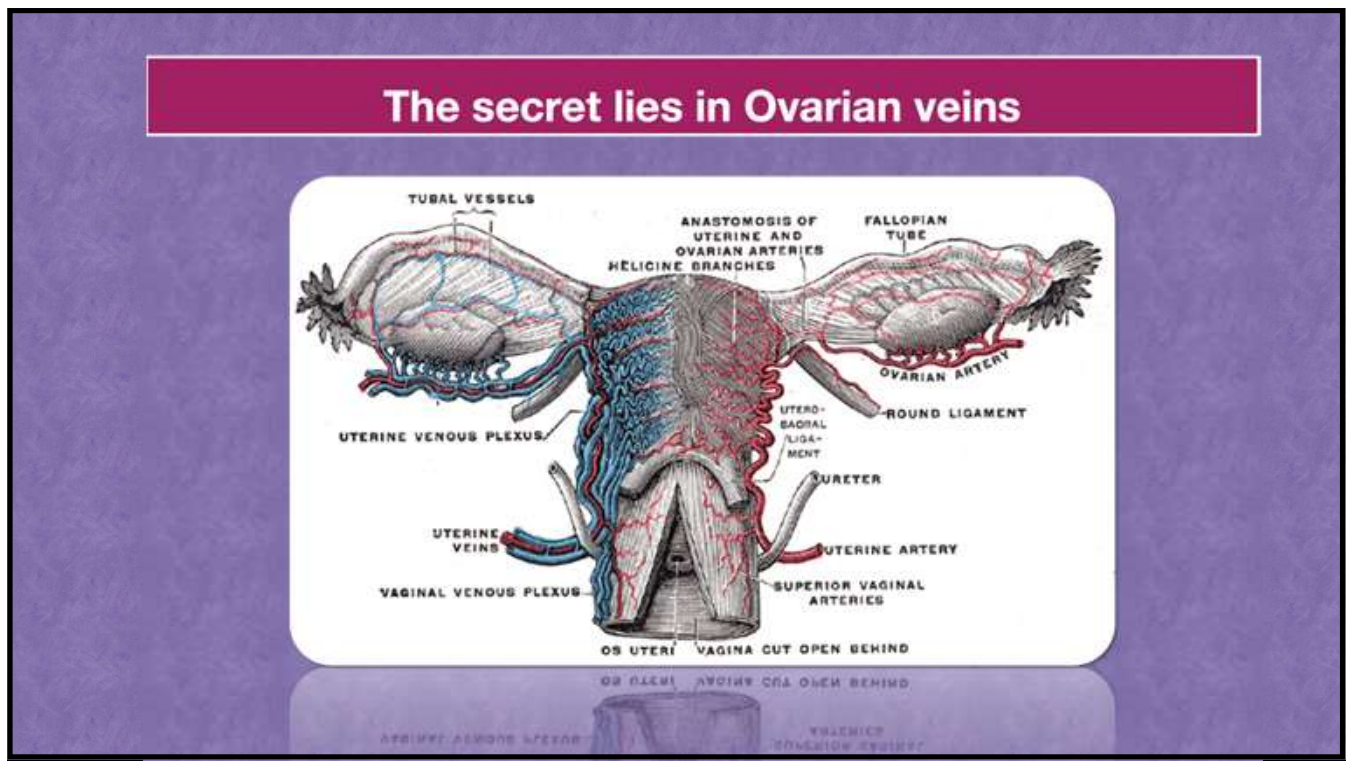

The secret lies in Ovarian veins

TUBAL VESSELS
ANASTOMOSIS OF UTERINE AND OVARIAN ARTERIES
HELICINE BRANCHES
FALLOPIAN TUBE
OVARIAN ARTERY
ROUND LIGAMENT
UTERINE VENOUS PLEXUS
UTERO-SACRAL LIGA-MENT
URETER
UTERINE VEINS
UTERINE ARTERY
VAGINAL VENOUS PLEXUS
SUPERIOR VAGINAL ARTERIES
OS UTERI
VAGINA CUT OPEN BEHIND

Innovations in anatomy

CERVICOVESICAL FASCIA

CERVICO - VESICAL FASCIA

Covers the cervix Anteriorly and Laterally
Continues as the Endopelvic Fascia as it reaches the Levator Ani

Bladder dissection will lie
Anterior to the fascia

↓

The venous plexus lies
Beneath the fascia

↓

The Uterine Vessels lie Above the fascia, thus exposing them

↓

The Vagina is accessible after dissection of the fascia for colpotomy

If these steps are followed sequentially,
would achieve bloodless dissection

BLADDER DISSECTION PRESERVING THE CERVICOVESICAL FASCIA (PUSH THE BLADDER AWAY)

the bladder, dissection to be done remaining above the cervicovesical fascia to stay away from the

CERVICO VESICAL FASCIA

Dissection of Cervicovescical fascia

IMPLICATIONS OF VEINS LYING UNDERNEATH THE FASCIA

- APPLIED - STAY ABOVE FASCIA
- IF WANTS TO CONTROL BLEEDING - HOLD & COAGULATE FASCIA BLEEDING WILL STOP

COLPOTOMY

- Colopotomy was done by separating the vagina anteriorly, from the posterior surface of bladder so as to get approximately 1.5 cms of vagina, and posteriorly, from rectum.

Transplant Surgery

Laparoscopic Dissection OF DONOR uterus

Laparoscopy Assisted Uterine transplant

Pedicle lengths achieved with Open surgery (Sweden)	Pedicle lengths achieved with Laparoscopic surgery
	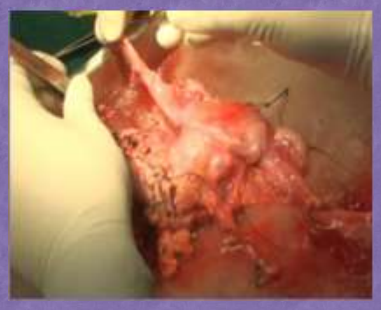

Perks of Laparoscopy

ADVANTAGES of Laparoscopy

SWEDEN 2012	INDIA 2018
Modality : Open	Modality: Laparoscopic
Total Duration : 14 hrs	Total Duration : 8-10 hrs
DURATION	DURATION
DONOR : 10 HR 7 MIN	DONOR : 4 HOURS
RECIPIENT : 4 HR 55 MIN	RECIPIENT : 4 HOURS
	TOTAL ISCHEMIC TIME : 45 MIN
BLOOD LOSS DONOR : 0.7 LT	BLOOD LOSS DONOR : 0.5 LT
RECIPIENT 0.6 LT	RECIPIENT : 0.5 LT
Outcome: Successful	Outcome: Successful
FIRST MENSES: 43 DAYS	FIRST MENSES: 48 DAYS

BENCH PREPARATION

Uterus was placed on ice slush flooded with cold Custodiol solution. Bilaterally, Internal Iliac artery and veins and Ovarian vessels were identified, dissected, skeletonized, terminal openings prepared and kept ready for anastomosis

BENCH SURGERY

GRAFT PREPARATION

Demonstrating utero ovarian anastomosis

VASCULAR BED PREPARATION

OUR CONTRIBUTION TO WORLD CONTINUES..



Novel Anastomotic Technique for Uterine Transplant Using Utero-ovarian Veins for Venous Drainage and Internal Iliac Arteries for Perfusion in Two Laparoscopically Harvested Uteri

Shailesh Puntambekar [1], Seema Puntambekar [2], Milind Telang [2], Pankaj Kulkarni [2], Shardul Date [3], Mangesh Panse [4], Ravindra Sathe [4], Nikhil Agarkhedkar [5], Neeta Warty [2], Sandesh Kade [2], Manoj Manchekar [4], Mihir Chitale [4], Hirav Parekh [4], Kajal Parikh [2], Mehul Mehta [4], Bhushan Kinholkar [6], Joy Shankar Jana [7], Avinash Pare [7], Shailendra Kanade [7], Abhay Sadre [8], Shirish Hardikar [9], Advait Jathar [4], Tejashree Bakre [2], Meenakshi Chate [2], Raviraj Tiruke [2]

Shailesh Puntambekar MS, Seema Puntambekar MS,
Milind Telang MD, Pankaj Kulkarni MD, Shardul Date MCH,
Mangesh Panse MS, Ravindra Sathe MS,
Nikhil Agarkhedkar MCH, Neeta Warty MS, Sandesh Kade MS,
Manoj Manchekar MS, Mihir Chitale FCPS, Hirav Parekh MS,
Kajal Parikh MS, Mehul Mehta MS, Bhushan Kinholkar MD,
Joy Shankar Jana MD, Avinash Pare MD,
Shailendra Kanade MD, Abhay Sadre DM, Shirish Hardikar MD,
Advait Jathar MS, Tejashree Bakre MS, Meenakshi Chate MS,
Raviraj Tiruke MS

PII:	S1553-4650(18)31431-6
DOI:	https://doi.org/10.1016/j.jmig.2018.11.021
Reference:	JMIG 3718

INDIA IS THE FIRST COUNTRY TO HAVE PERFORMED UTERUS TRANSPLANT IN HUMANS IN ASIA!

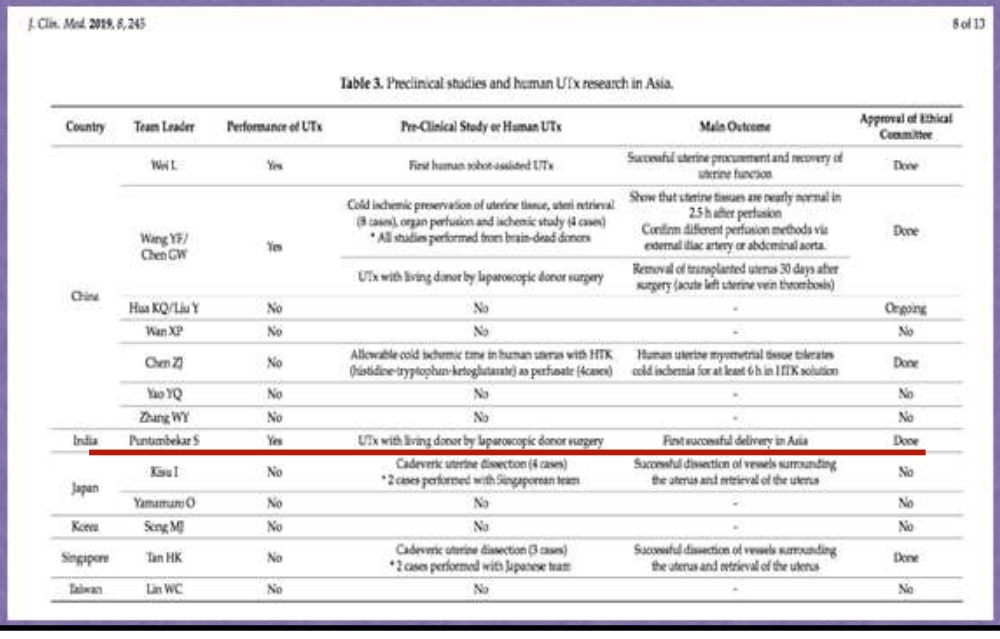

J. Clin. Med. 2019, 8, 245 — 8 of 13

Table 3. Preclinical studies and human UTx research in Asia.

Country	Team Leader	Performance of UTx	Pre-Clinical Study or Human UTx	Main Outcome	Approval of Ethical Committee
China	Wei L	Yes	First human robot-assisted UTx	Successful uterine procurement and recovery of uterine function	Done
	Wang YF/ Chen GW	Yes	Cold ischemic preservation of uterine tissue, uteri retrieval (8 cases), organ perfusion and ischemic study (4 cases) * All studies performed from brain-dead donors	Show that uterine tissues are nearly normal in 2.5 h after perfusion Confirm different perfusion methods via external iliac artery or abdominal aorta.	Done
			UTx with living donor by laparoscopic donor surgery	Removal of transplanted uterus 30 days after surgery (acute left uterine vein thrombosis)	
	Hua KQ/Liu Y	No	No	-	Ongoing
	Wan XP	No	No	-	No
	Chen ZJ	No	Allowable cold ischemic time in human uterus with HTK (histidine-tryptophan-ketoglutarate) as perfusate (4cases)	Human uterine myometrial tissue tolerates cold ischemia for at least 6 h in HTK solution	Done
	Yao YQ	No	No	-	No
	Zhang WY	No	No	-	No
India	Puntambekar S	Yes	UTx with living donor by laparoscopic donor surgery	First successful delivery in Asia	Done
Japan	Kisu I	No	Cadeveric uterine dissection (4 cases) * 2 cases performed with Singaporean team	Successful dissection of vessels surrounding the uterus and retrieval of the uterus	No
	Yamamuro O	No	No	-	No
Korea	Seng MJ	No	No	-	No
Singapore	Tan HK	No	Cadeveric uterine dissection (3 cases) * 2 cases performed with Japanese team	Successful dissection of vessels surrounding the uterus and retrieval of the uterus	Done
Taiwan	Lin WC	No	No	-	No

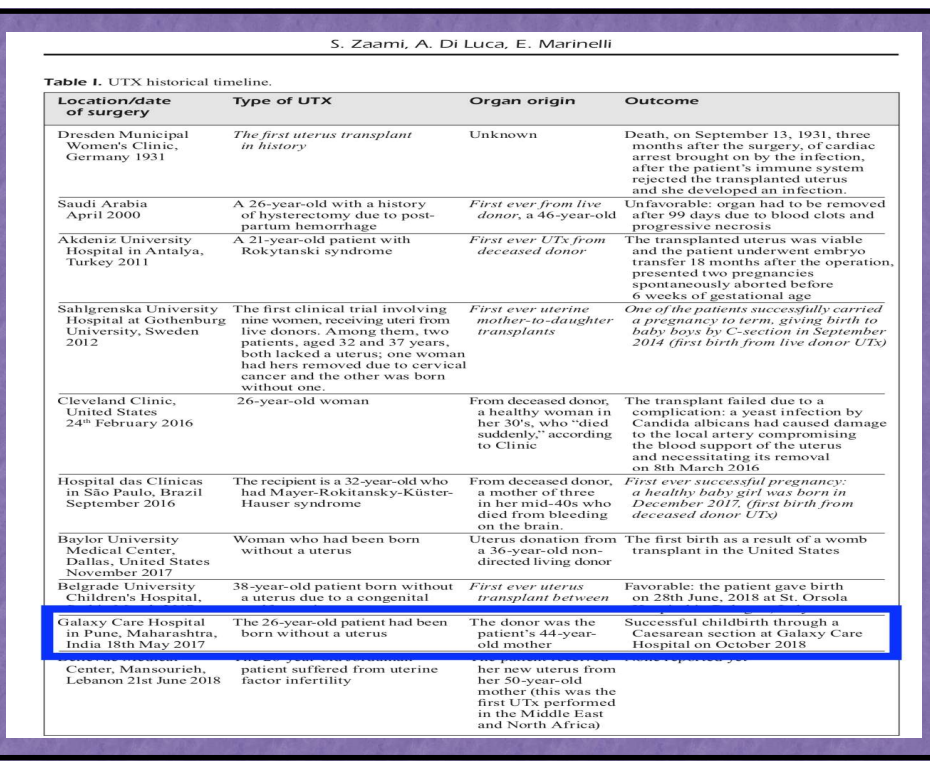

S. Zaami, A. Di Luca, E. Marinelli

Table 1. UTX historical timeline.

Location/date of surgery	Type of UTX	Organ origin	Outcome
Dresden Municipal Women's Clinic, Germany 1931	*The first uterus transplant in history*	Unknown	Death, on September 13, 1931, three months after the surgery, of cardiac arrest brought on by the infection, after the patient's immune system rejected the transplanted uterus and she developed an infection.
Saudi Arabia April 2000	A 26-year-old with a history of hysterectomy due to post-partum hemorrhage	*First ever from live donor*, a 46-year-old	Unfavorable: organ had to be removed after 99 days due to blood clots and progressive necrosis
Akdeniz University Hospital in Antalya, Turkey 2011	A 21-year-old patient with Rokytanski syndrome	*First ever UTx from deceased donor*	The transplanted uterus was viable and the patient underwent embryo transfer 18 months after the operation, presented two pregnancies spontaneously aborted before 6 weeks of gestational age
Sahlgrenska University Hospital at Gothenburg University, Sweden 2012	The first clinical trial involving nine women, receiving uteri from live donors. Among them, two patients, aged 32 and 37 years, both lacked a uterus; one woman had hers removed due to cervical cancer and the other was born without one.	*First ever uterine mother-to-daughter transplants*	*One of the patients successfully carried a pregnancy to term, giving birth to baby boys by C-section in September 2014 (first birth from live donor UTx)*
Cleveland Clinic, United States 24th February 2016	26-year-old woman	From deceased donor, a healthy woman in her 30's, who "died suddenly," according to Clinic	The transplant failed due to a complication: a yeast infection by Candida albicans had caused damage to the local artery compromising the blood support of the uterus and necessitating its removal on 8th March 2016
Hospital das Clínicas in São Paulo, Brazil September 2016	The recipient is a 32-year-old who had Mayer-Rokitansky-Küster-Hauser syndrome	From deceased donor, a mother of three in her mid-40s who died from bleeding on the brain.	*First ever successful pregnancy: a healthy baby girl was born in December 2017. (first birth from deceased donor UTx)*
Baylor University Medical Center, Dallas, United States November 2017	Woman who had been born without a uterus	Uterus donation from a 36-year-old non-directed living donor	The first birth as a result of a womb transplant in the United States
Belgrade University Children's Hospital,	38-year-old patient born without a uterus due to a congenital	*First ever uterus transplant between*	Favorable: the patient gave birth on 28th June, 2018 at St. Orsola
Galaxy Care Hospital in Pune, Maharashtra, India 18th May 2017	The 26-year-old patient had been born without a uterus	The donor was the patient's 44-year-old mother	Successful childbirth through a Caesarean section at Galaxy Care Hospital on October 2018
Center, Mansourieh, Lebanon 21st June 2018	patient suffered from uterine factor infertility	her new uterus from her 50-year-old mother (this was the first UTx performed in the Middle East and North Africa)	

OUR SUCCESS WAS CELEBRATED BEFORE THE WORLD AT GLOBAL CONGRESS OF AMERICAN ASSOCIATION OF GYNAECOLOGICAL LAPAROSCOPISTS IN 2018

47th AAGL Global Congress on MIGS
AAGL
ELEVATING GYNECOLOGIC SURGERY
Las Vegas, Nevada November 11-15, 2018

AAGL
2018 Global Congress
MGM GRAND LAS VEGAS, NV NOV 11-15, 2018

WHEN OUR WORK WAS ACKNOWLEDGED…

RECENT PUBLICATIONS
WE CONTRIBUTED
TO SCIENCE!

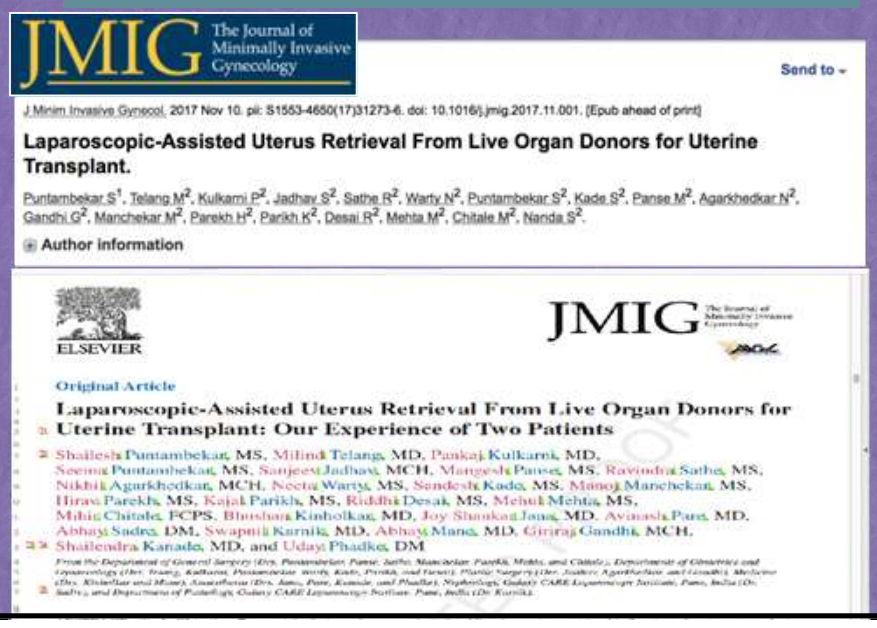

J Minim Invasive Gynecol. 2017 Nov 10. pii: S1553-4650(17)31273-6. doi: 10.1016/j.jmig.2017.11.001. [Epub ahead of print]

Laparoscopic-Assisted Uterus Retrieval From Live Organ Donors for Uterine Transplant.

Puntambekar S[1], Telang M[2], Kulkarni P[2], Jadhav S[2], Sathe R[2], Warty N[2], Puntambekar S[2], Kade S[2], Panse M[2], Agarkhedkar N[2], Gandhi G[2], Manchekar M[2], Parekh H[2], Parikh K[2], Desai R[2], Mehta M[2], Chitale M[2], Nanda S[2].

⊞ Author information

Original Article

Laparoscopic-Assisted Uterus Retrieval From Live Organ Donors for Uterine Transplant: Our Experience of Two Patients

Shailesh Puntambekar, MS, Milind Telang, MD, Pankaj Kulkarni, MD, Seema Puntambekar, MS, Sanjeev Jadhav, MCH, Mangesh Panse, MS, Ravindra Sathe, MS, Nikhil Agarkhedkar, MCH, Neeta Warty, MS, Sandesh Kade, MS, Manoj Manchekar, MS, Hirav Parekh, MS, Kajal Parikh, MS, Riddhi Desai, MS, Mehul Mehta, MS, Mihir Chitale, FCPS, Bhushan Kinholkar, MD, Joy Shankar Jana, MD, Avinash Pare, MD, Abhay Sadre, DM, Swapnil Karnik, MD, Abhay Mane, MD, Giriraj Gandhi, MCH, Shailendra Kanade, MD, and Uday Phadke, DM

RECENT PUBLICATIONS
WE CONTRIBUTED
TO SCIENCE!

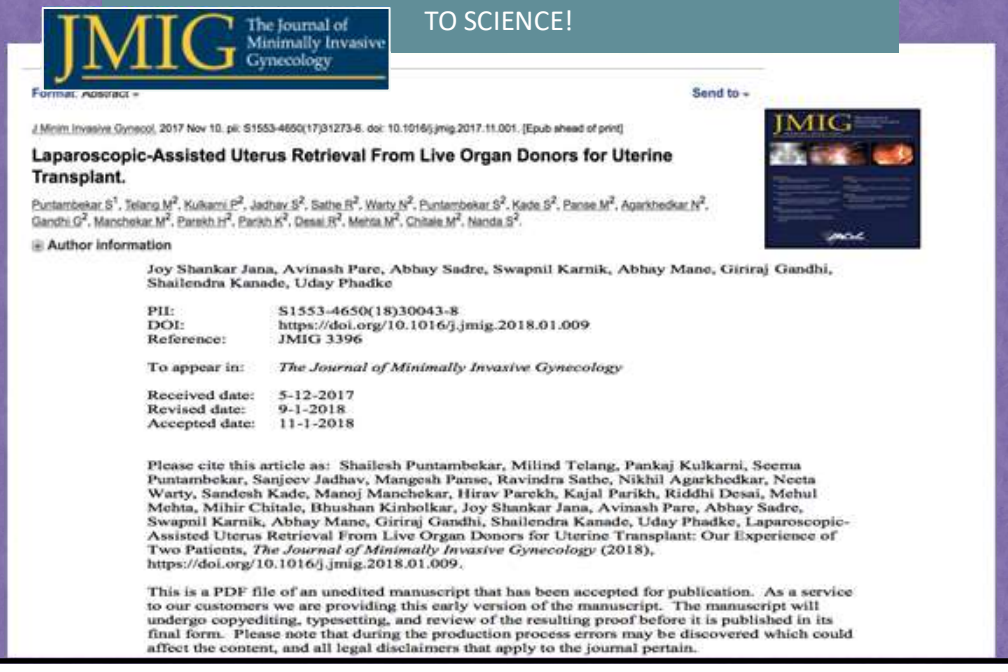

J Minim Invasive Gynecol. 2017 Nov 10. pii: S1553-4650(17)31273-6. doi: 10.1016/j.jmig.2017.11.001. [Epub ahead of print]

Laparoscopic-Assisted Uterus Retrieval From Live Organ Donors for Uterine Transplant.

Puntambekar S[1], Telang M[2], Kulkarni P[2], Jadhav S[2], Sathe R[2], Warty N[2], Puntambekar S[2], Kade S[2], Panse M[2], Agarkhedkar N[2], Gandhi G[2], Manchekar M[2], Parekh H[2], Parikh K[2], Desai R[2], Mehta M[2], Chitale M[2], Nanda S[2].

⊞ Author information

Joy Shankar Jana, Avinash Pare, Abhay Sadre, Swapnil Karnik, Abhay Mane, Giriraj Gandhi, Shailendra Kanade, Uday Phadke

PII:	S1553-4650(18)30043-8
DOI:	https://doi.org/10.1016/j.jmig.2018.01.009
Reference:	JMIG 3396
To appear in:	*The Journal of Minimally Invasive Gynecology*
Received date:	5-12-2017
Revised date:	9-1-2018
Accepted date:	11-1-2018

Please cite this article as: Shailesh Puntambekar, Milind Telang, Pankaj Kulkarni, Seema Puntambekar, Sanjeev Jadhav, Mangesh Panse, Ravindra Sathe, Nikhil Agarkhedkar, Neeta Warty, Sandesh Kade, Manoj Manchekar, Hirav Parekh, Kajal Parikh, Riddhi Desai, Mehul Mehta, Mihir Chitale, Bhushan Kinholkar, Joy Shankar Jana, Avinash Pare, Abhay Sadre, Swapnil Karnik, Abhay Mane, Giriraj Gandhi, Shailendra Kanade, Uday Phadke, Laparoscopic-Assisted Uterus Retrieval From Live Organ Donors for Uterine Transplant: Our Experience of Two Patients, *The Journal of Minimally Invasive Gynecology* (2018), https://doi.org/10.1016/j.jmig.2018.01.009.

This is a PDF file of an unedited manuscript that has been accepted for publication. As a service to our customers we are providing this early version of the manuscript. The manuscript will undergo copyediting, typesetting, and review of the resulting proof before it is published in its final form. Please note that during the production process errors may be discovered which could affect the content, and all legal disclaimers that apply to the journal pertain.

OUR CONTRIBUTION TO WORLD CONTINUES…

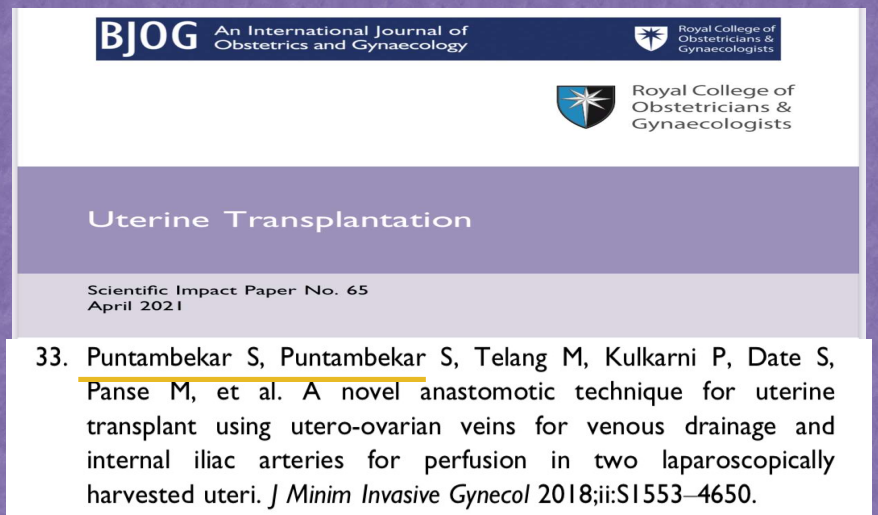
BJOG An International Journal of Obstetrics and Gynaecology
Royal College of Obstetricians & Gynaecologists
Royal College of Obstetricians & Gynaecologists

Uterine Transplantation

Scientific Impact Paper No. 65
April 2021

33. Puntambekar S, Puntambekar S, Telang M, Kulkarni P, Date S, Panse M, et al. A novel anastomotic technique for uterine transplant using utero-ovarian veins for venous drainage and internal iliac arteries for perfusion in two laparoscopically harvested uteri. *J Minim Invasive Gynecol* 2018;ii:S1553–4650.

WE HAVE BEEN CITED BY…

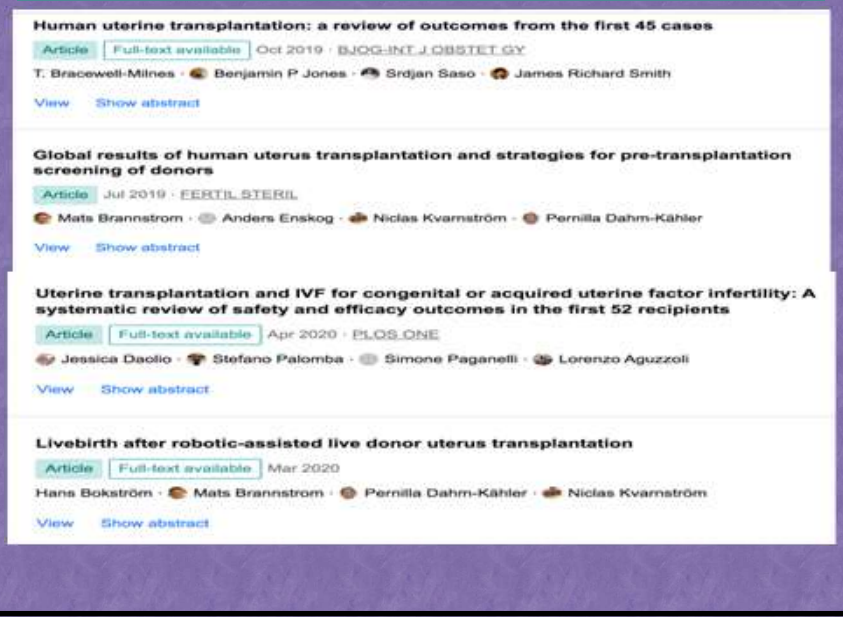

Human uterine transplantation: a review of outcomes from the first 45 cases

Article | Full-text available | Oct 2019 · BJOG-INT J OBSTET GY

T. Bracewell-Milnes · Benjamin P Jones · Srdjan Saso · James Richard Smith

View Show abstract

Global results of human uterus transplantation and strategies for pre-transplantation screening of donors

Article | Jul 2019 · FERTIL STERIL

Mats Brannstrom · Anders Enskog · Niclas Kvarnström · Pernilla Dahm-Kähler

View Show abstract

Uterine transplantation and IVF for congenital or acquired uterine factor infertility: A systematic review of safety and efficacy outcomes in the first 52 recipients

Article | Full-text available | Apr 2020 · PLOS ONE

Jessica Daolio · Stefano Palomba · Simone Paganelli · Lorenzo Aguzzoli

View Show abstract

Livebirth after robotic-assisted live donor uterus transplantation

Article | Full-text available | Mar 2020

Hans Bokström · Mats Brannstrom · Pernilla Dahm-Kähler · Niclas Kvarnström

View Show abstract

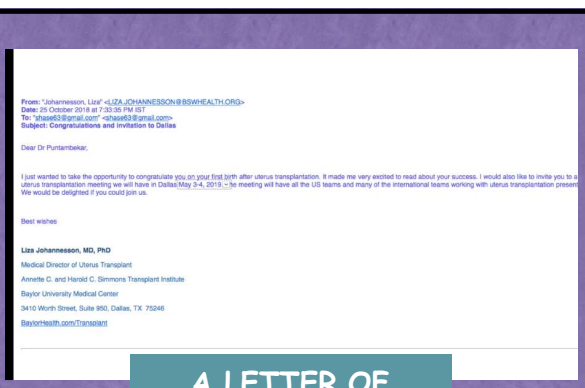

From: "Johannesson, Liza" <LIZA.JOHANNESSON@BSWHEALTH.ORG>
Date: 25 October 2018 at 7:33:35 PM IST
To: "shase63@gmail.com" <shase63@gmail.com>
Subject: Congratulations and invitation to Dallas

Dear Dr Puntambekar,

I just wanted to take the opportunity to congratulate you on your first birth after uterus transplantation. It made me very excited to read about your success. I would also like to invite you to a uterus transplantation meeting we will have in Dallas May 3-4, 2019. he meeting will have all the US teams and many of the international teams working with uterus transplantation present We would be delighted if you could join us.

Best wishes

Liza Johannesson, MD, PhD
Medical Director of Uterus Transplant
Annette C. and Harold C. Simmons Transplant Institute
Baylor University Medical Center
3410 Worth Street, Suite 950, Dallas, TX 75246
BaylorHealth.com/Transplant

A LETTER OF APPRECIATION MEANT A LOT

"If no one can repeat it. Its not worth Anything. We owe to the patients to be open."
-Dr. Liza Johannesson
Co surgeon to the world first uterine transplant giving a statement to TIME MAGAZINE

WE DID NOT ONLY THE FIRST LAPAROSCOPIC RETRIEVAL OF DONOR UTERUS

BUT ALSO THE FIRST CENTRE FOR LAPAROSCOPIC VASCULAR ANASTAMOSIS

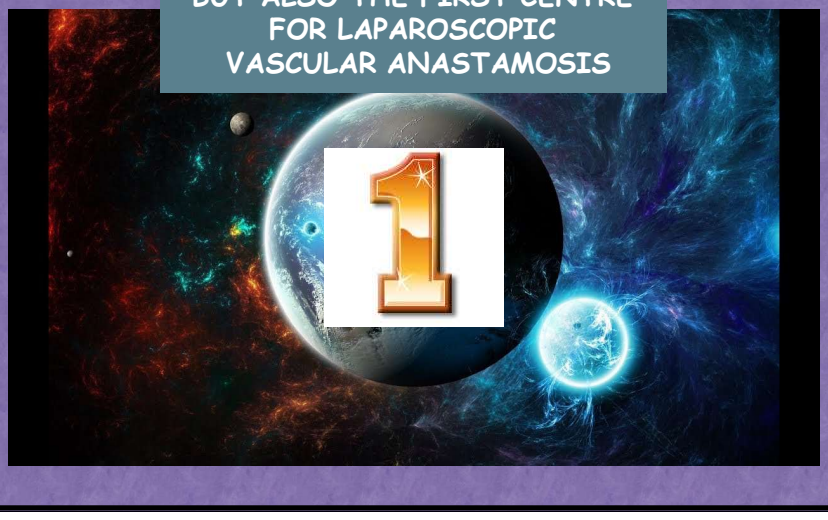

Covid

1.no transplants could be done

2.patients were not able to take immunosuppressants

3.second patient is pregnant

4.world wide transplant programmes have taken back seat

---

current status

1.Cadaveric transplants done in two patients

2.Robotic donor uterine transplants done

3.Spain and Brazil did the transplant using our technique of ovarian veins

4.more than 90 transplants done

5.forty three babies delivered

POST OPERATIVE MONITORING

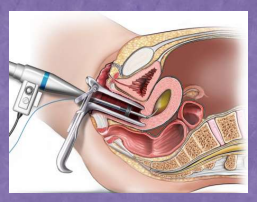

- Routine Blood Investigations
  - Specific Investigations-

Non- Invasive
- USG TO MEASURE ET, ECHOGENESITY
- Colour Doppler - TO MEASURE VELOCITY IN ANASTOMOTIC VESSELS

Invasive
- Colposcopic Examination,
- BiopsyTO DETECT EARLIEST MANIFESTATION OF REJIN CONFIRMED MANNER ECTION

Hysteroscopy : the best tool for detection of early graft rejection

DOPPLER FLOW

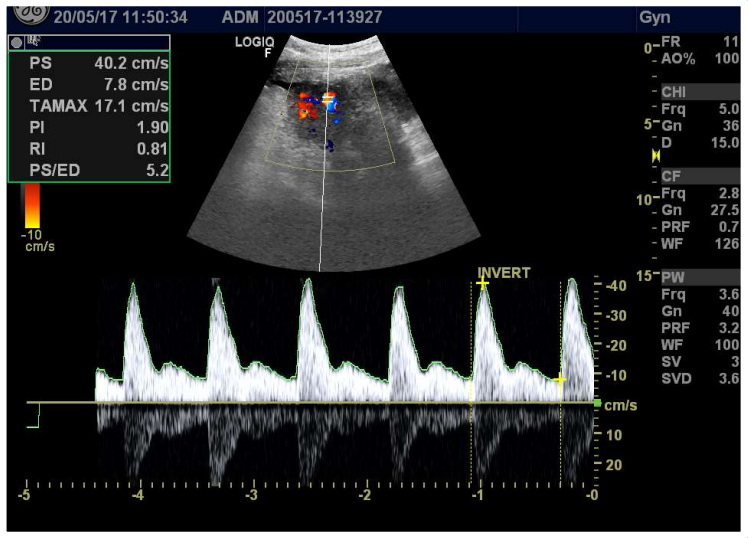
20/05/17 11:50:34
ADM 200517-113927
Gyn
LOGIQ
PS 40.2 cm/s
ED 7.8 cm/s
TAMAX 17.1 cm/s
PI 1.90
RI 0.81
PS/ED 5.2
INVERT
cm/s

Doppler Images And Videos

DOPPLER S/O DECREASED FLOW

POST UTX PT WITH
DECRESED FLOW AFTER
1 YEAR
GIVEN
INJ HEPARINE PRIOR TO
IVF

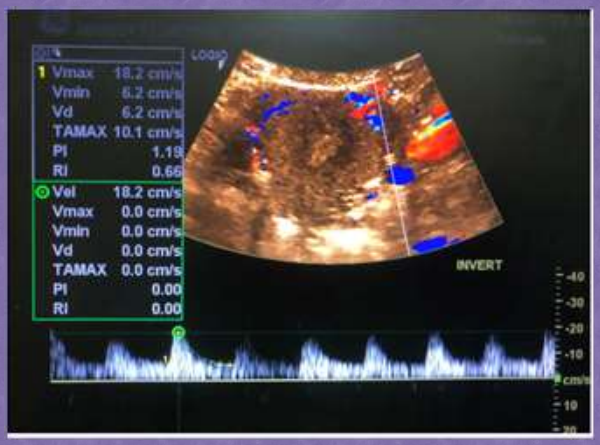
1 Vmax 18.2 cm/s
Vmin 6.2 cm/s
Vd 6.2 cm/s
TAMAX 10.1 cm/s
PI 1.19
RI 0.66
Vel 18.2 cm/s
Vmax 0.0 cm/s
Vmin 0.0 cm/s
Vd 0.0 cm/s
TAMAX 0.0 cm/s
PI 0.00
RI 0.00
LOGIQ
INVERT

Challenges During Ivf

1. Unpredictable ovarian response .
2. Which protocol to be used?
3. Challanges in titrating gonadotropin dose rationale.
4. Difficult ovum pickup-

Ovaries are lateral to external iliac vessels in women with uterine agenesis.

Bowel/bladder injury.

5. Different anatomy (pelvic kidneys-MRKH2).
6. Poor quality embryos.
7. Increase chance of cycle cancellation.
8. Change in axis and cervical stenosis,small vagina-

Difficult et

9.Improper vaginiplasty,higher placement of uterus, fibrosis between vagina and external os- difficult et.

10.All procedures under GA

11. Abdominal et (may required).

Difficulty In Embryo Transfer

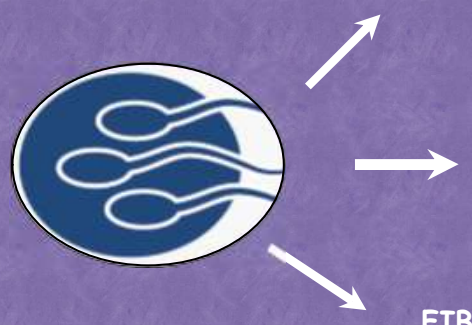

IMPROPER VAGINOPLASTY

HIGHER PLACEMENT OF UTERUS

FIBROSIS BETWEEN VAGINA & EXTERNAL OS CAUSING STENOSED CERVIX

Embryo transfer

DIFFICULTIES IN IMPLANTATION

- ENDOMETRIUM PRIMING AFTER CERTAIN AGE NOT GOOD
- HIGHER RESISTANCE IN UTERINE ARTERIES IN DONOR UTERUS
- RECEPTIVITY OF ENDOMETRIUM NOT GOOD
- DISTENSIBILITY OF UTERUS IS AT RISK
- IMMUNOLOGICAL FACTORS

ONLY 30% IS FERTILITY RATE AT ANY GOOD IVF CENTERS

DIFFICULTIES IN TEAM UP

- IN INDIA -SINCE LAST 3YEARS NO STATE HAS GIVEN COMMITTEE APPROVAL ONE OF FACTOR BEING COVID PANDEMIC
- UTX TEAM WORK TASK -ALL DOCTORS (SURGEONS,OBGYN,VASCULAR SURGEON,ANAESTHEIST ETC.) TO COME TOGETHER IS DIFFICULT

Removal

Removal of Uterus (Hysterectomy) to be done :

✦After completion of Family

✦Signs of Graft Rejection

✦Signs of Infection/Septicaemia

Complication Post Transplant

Post Transplant Hysterectomy

Atrophic uterus post Uterine Transplant

LESSONS WE LEARNT…

- ❖UTX IS COMPLETE ANSWER TO ABSOLUTE UTERINE FACTOR INFERTILITY
- ❖UTERO-OVARIAN ANASTOMOSIS
- ❖SINGLE SIDE VASCULAR ANASTOMOSIS IS SUFFICIENT
- ❖OMENTAL WRAPPING OF URTER OR PROPHYLACTIC DJ-STENTING TO PREVENT URETERIC FISTULAS
- ❖LAPAROSCOPIC ASSISTED DONAR RETRIEVAL OF UTERUS- long pedicle lengths AND Wider anastomosis
- ❖BETTER VASCULARITY TO THE ORGAN ,BETTER ADAPTATION DURING PREGNANCY TO ACCOMMODATE EXTRA BLOOD FLOW.

LESSONS WE LEARNT…

- ❖IMMUNOSUPPRESANT SHOULD GIVE ONE DAY PRIOR TO SURGERY AND SHOULD CONTINUE FROM POST OP DAY ONE.
- ❖RIGOROUS POSTOP MONITORING -to detect early signs of rejection
- ❖EMBRYO TRANSFER SHOULD NOT DELAY MORE THAN 6 MONTHS
- ❖MORBIDITY AND MORTALITY IS VERY LESS

AGAIN MADE HISTORY

- 1ST POST COVID UTERINE TRANSPLANTS
- 2 TRANSPLANTS IN ONE DAY IN RECORD BREAKING TIME (<12 HOURS)
- THAT TOO IN OTHER CENTER

TOI

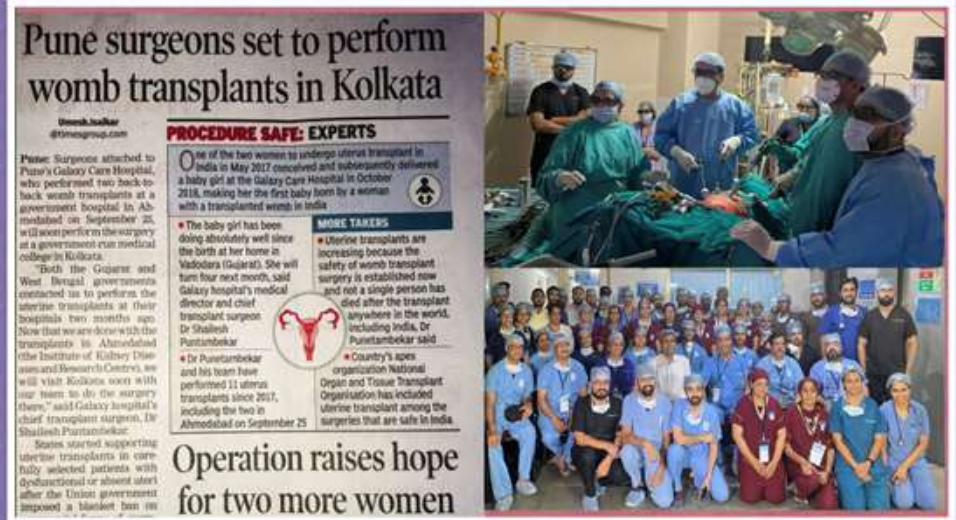

Pune surgeons set to perform womb transplants in Kolkata

Umesh Isalkar
@timesgroup.com

Pune: Surgeons attached to Pune's Galaxy Care Hospital, who performed two back-to-back womb transplants at a government hospital in Ahmedabad on September 25, will soon perform the surgery at a government-run medical college in Kolkata.

"Both the Gujarat and West Bengal governments contacted us to perform the uterine transplants at their hospitals two months ago. Now that we are done with the transplants in Ahmedabad (the Institute of Kidney Diseases and Research Centre), we will visit Kolkata soon with our team to do the surgery there," said Galaxy hospital's chief transplant surgeon, Dr Shailesh Puntambekar.

States started supporting uterine transplants in carefully selected patients with dysfunctional or absent uteri after the Union government imposed a blanket ban on

PROCEDURE SAFE: EXPERTS

One of the two women to undergo uterus transplant in India in May 2017 conceived and subsequently delivered a baby girl at the Galaxy Care Hospital in October 2018, making her the first baby born by a woman with a transplanted womb in India

- The baby girl has been doing absolutely well since the birth at her home in Vadodara (Gujarat). She will turn four next month, said Galaxy hospital's medical director and chief transplant surgeon Dr Shailesh Puntambekar
- Dr Puntambekar and his team have performed 11 uterus transplants since 2017, including the two in Ahmedabad on September 25

MORE TAKERS

- Uterine transplants are increasing because the safety of womb transplant surgery is established now and not a single person has died after the transplant anywhere in the world, including India, Dr Puntambekar said
- Country's apex organization National Organ and Tissue Transplant Organisation has included uterine transplant among the surgeries that are safe in India

Operation raises hope for two more women

AGAIN MADE HISTORY

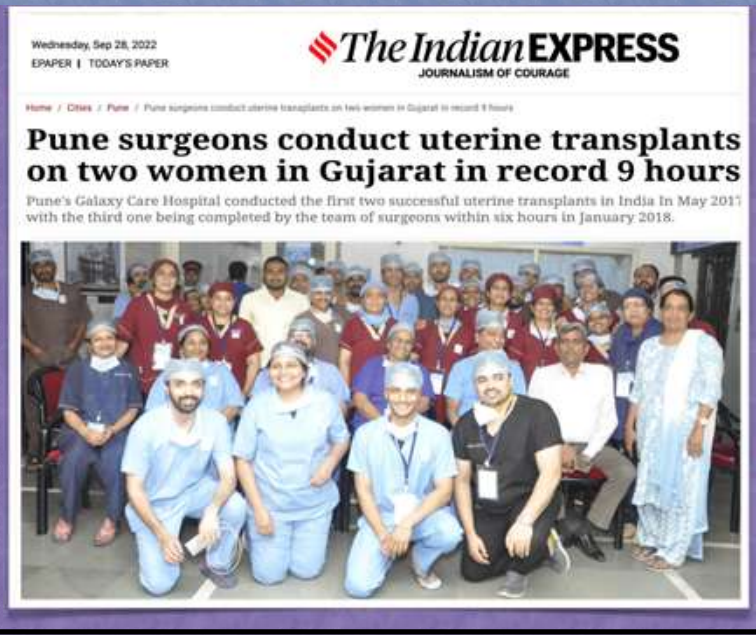

Wednesday, Sep 28, 2022
EPAPER | TODAY'S PAPER

The Indian EXPRESS
JOURNALISM OF COURAGE

Home / Cities / Pune / Pune surgeons conduct uterine transplants on two women in Gujarat in record 9 hours

Pune surgeons conduct uterine transplants on two women in Gujarat in record 9 hours

Pune's Galaxy Care Hospital conducted the first two successful uterine transplants in India in May 2017 with the third one being completed by the team of surgeons within six hours in January 2018.

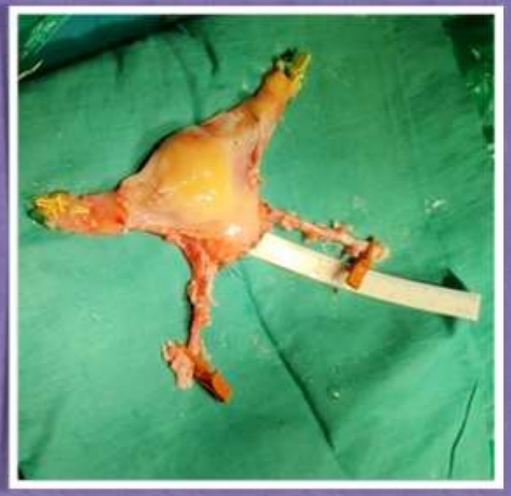

UTERINE PEDICAL ACHIEVED IN DONOR

AGAIN MADE HISTORY

THERE ARE 3 'C's of success

- COMPASSION
- COURAGE
- CRAZINESS

Fly Emirates

Thank you….

Masters Course in Exposure, Retraction & Deep Dissection:

Challenging Robotic Surgeries

Kristin Patzkowsky, MD
Assistant Professor of Gynecology
Director, Fellowship Minimally Invasive Gynecologic Surgery
Johns Hopkins School of Medicine
Baltimore, MD

December 1, 2022

AAGL 2022
51st GLOBAL CONGRESS ON MIGS
December 1-4, 2022 | Aurora, CO | congress.aagl.org

Disclosure

- **I have no financial relationships to disclose**.

What's Challenging?

- **Advanced Endometriosis**
- High order myomectomies
- Massive uteri hysterectomy
- C-section scar defect repair

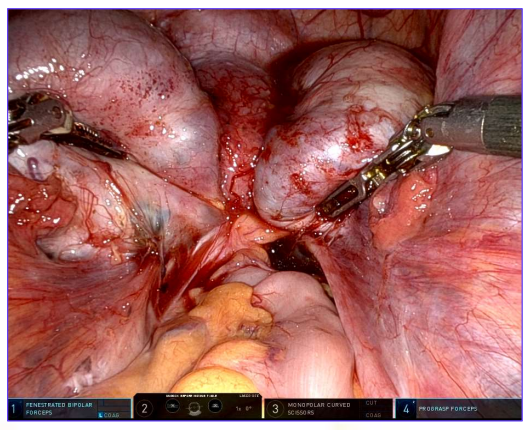

What's Challenging?

- Advanced Endometriosis
- **High order myomectomies**
- Massive uteri hysterectomy
- C-section scar defect repair

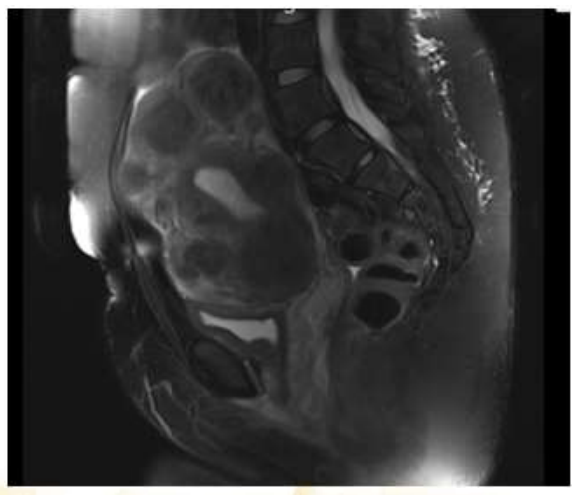

What's Challenging?

- Advanced Endometriosis
- High order myomectomies
- **Massive uteri hysterectomy**
- C-section scar defect repair

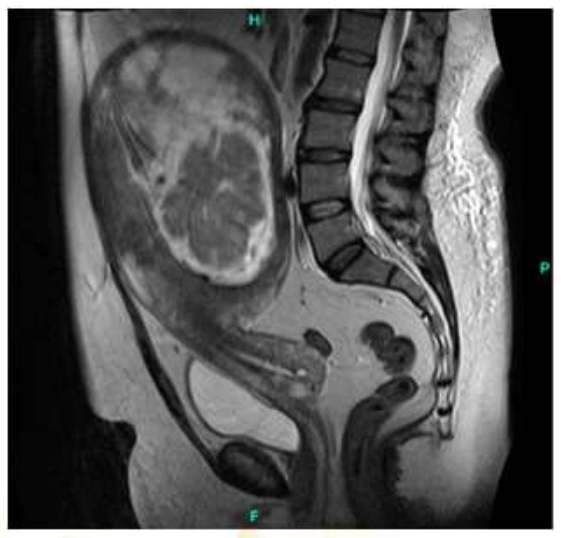

What's Challenging?

- Advanced Endometriosis
- High order myomectomies
- Massive uteri hysterectomy
- **C-section scar defect repair**

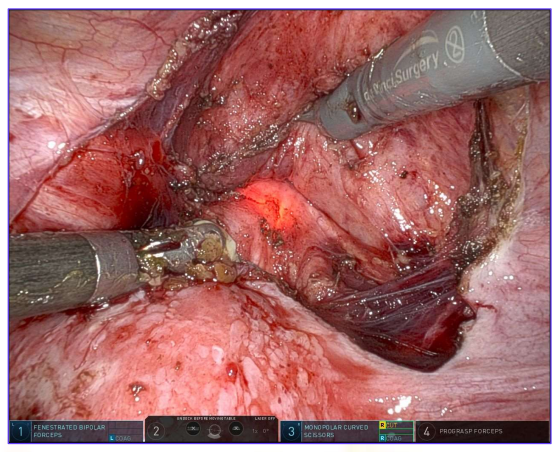

What's Challenging?

- **Combo Pathology**
- **Obliterated Pathology**

Objectives

- Illustrate techniques for tackling complex MIS surgical scenarios
- Recommend strategies for approaching complex pathology
- Discuss ways the robotic platform can be utilized to simplify challenging pathology

---

COMBO PATHOLOGY

CASE #1

37yo G1P1 s/p abd myomectomy with recurrent fibroids & bulk symptoms.

- Exam: midline vertical incision, 2cm supraumbilical hernia, 22wk size fibroid uterus with a cervical fibroid filling posterior cul-de-sac and deviating cervix anteriorly
- Procedure: TRH, BS
- EBL: 500cc
- Specimen weight: 1153g

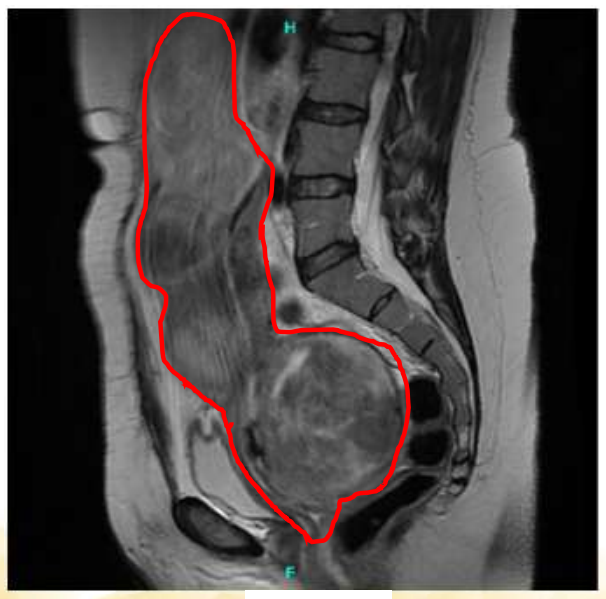

T2 Sagittal

CASE #1: 22wk Fibroid Uterus with 10cm Cervical Fibroid

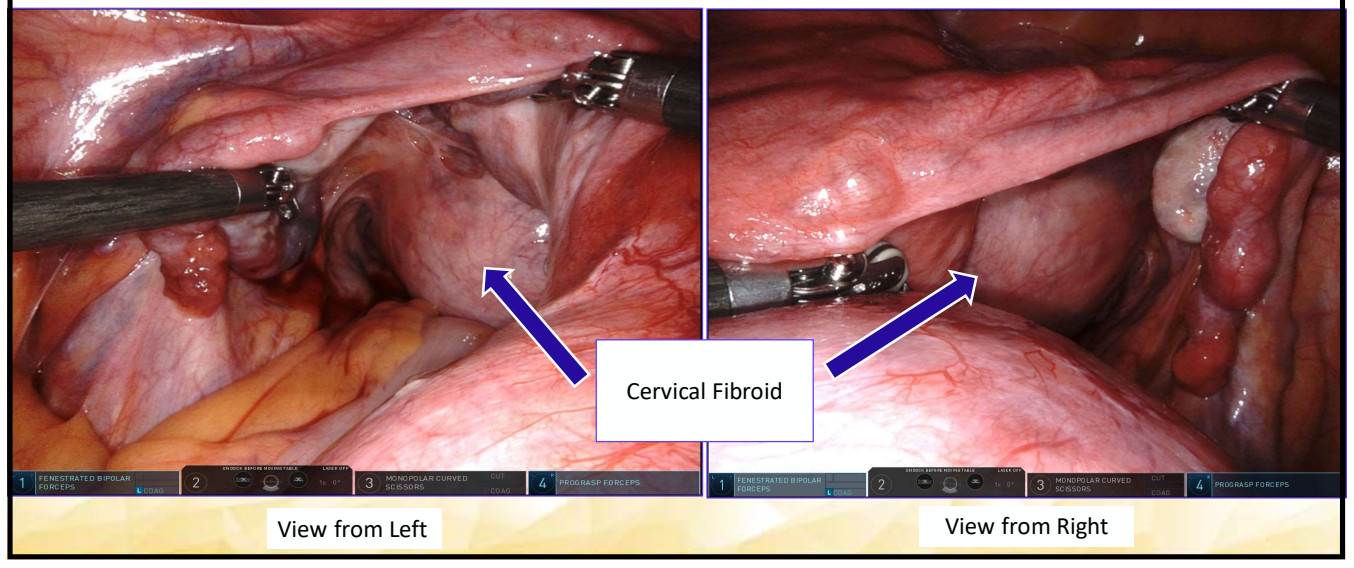

View from Left

View from Right

CASE #1: Total robotic hysterectomy for 22wk size fibroid uterus with 10cm cervical fibroid

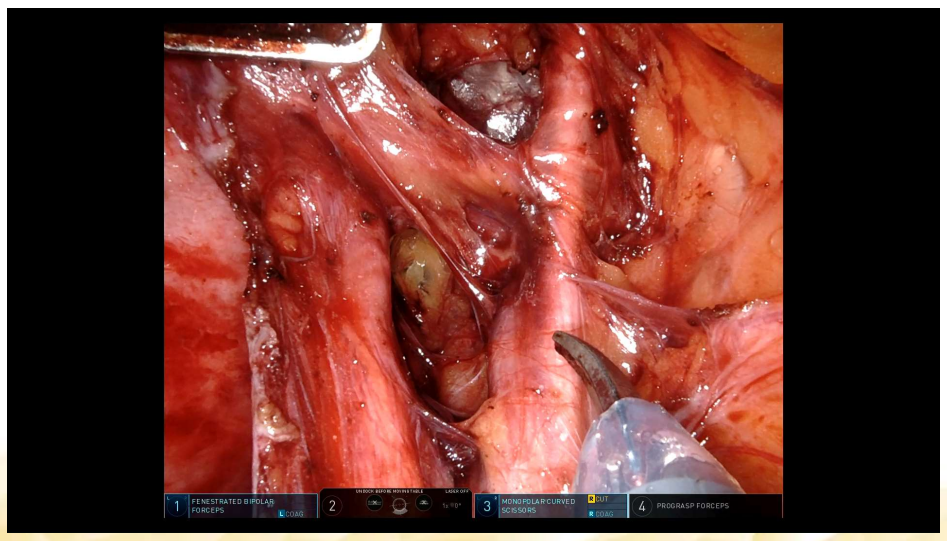

CASE #2

45yo G1P0 s/p robotic LSO for stg IV endometriosis with recurrent pain & bleeding.

- Exam: 18wk size uterus, restricted mobility, short torso, narrow pelvis
- MRI: right ovarian endometrioma, adenomyosis and fibroids

- Procedure: TRH, RSO
- EBL: 150cc
- Specimen weight: 610g

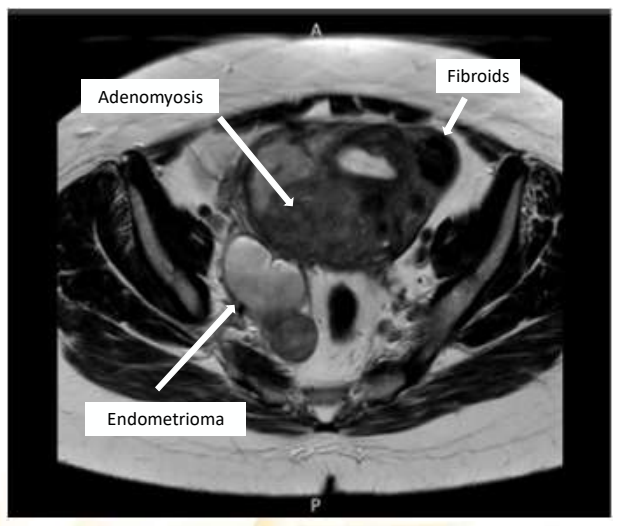

T2 Axial

CASE #2: 18wk Uterus with Stg IV endometriosis

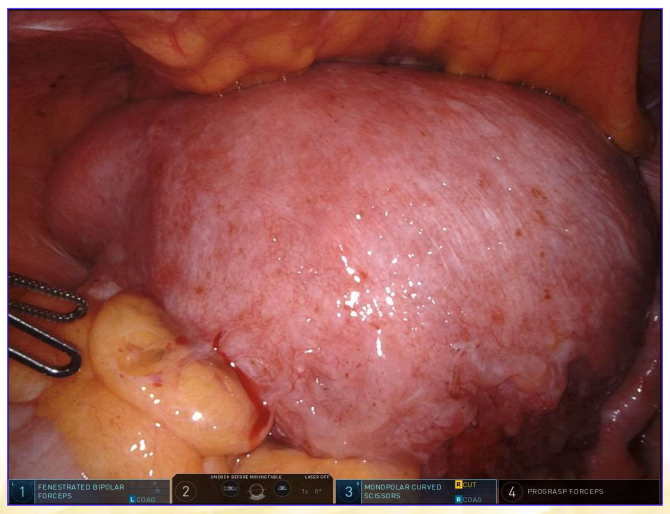

Global View of Pelvis

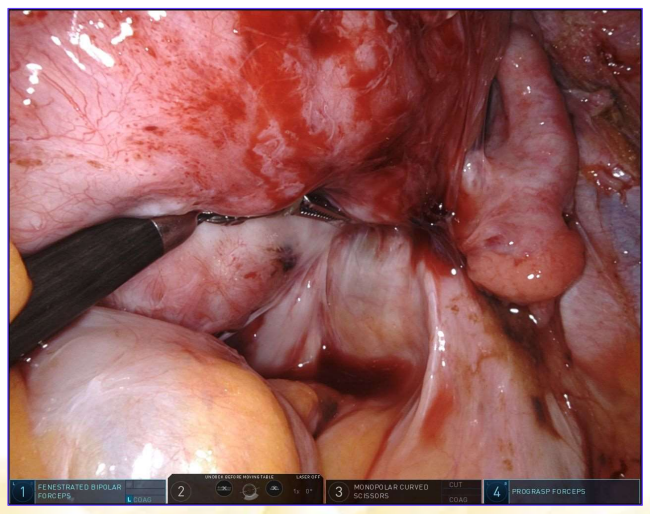

Obliterated Right Adnexa

CASE #2: Total robotic hysterectomy, RSO for fibroids, adenomyosis and stg IV endometriosis

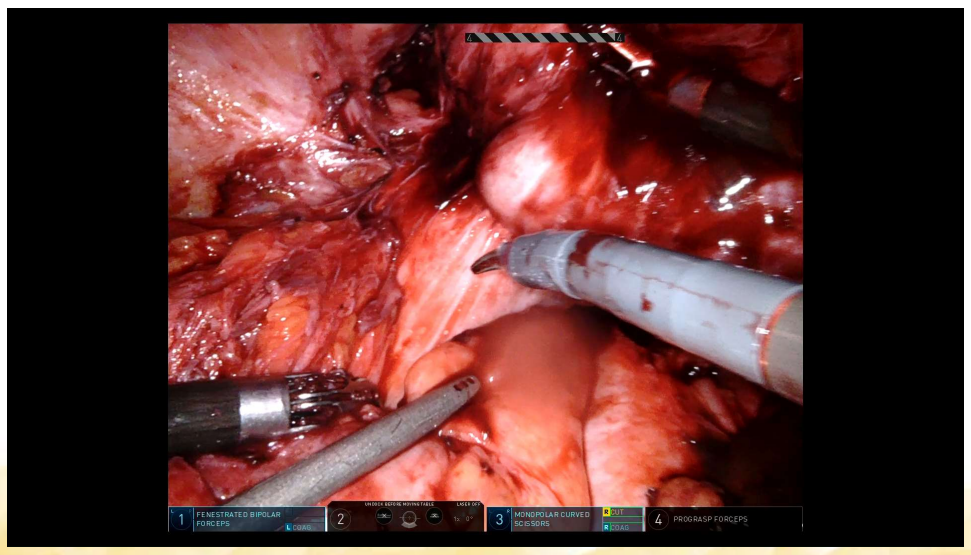

Set It & Forget It!

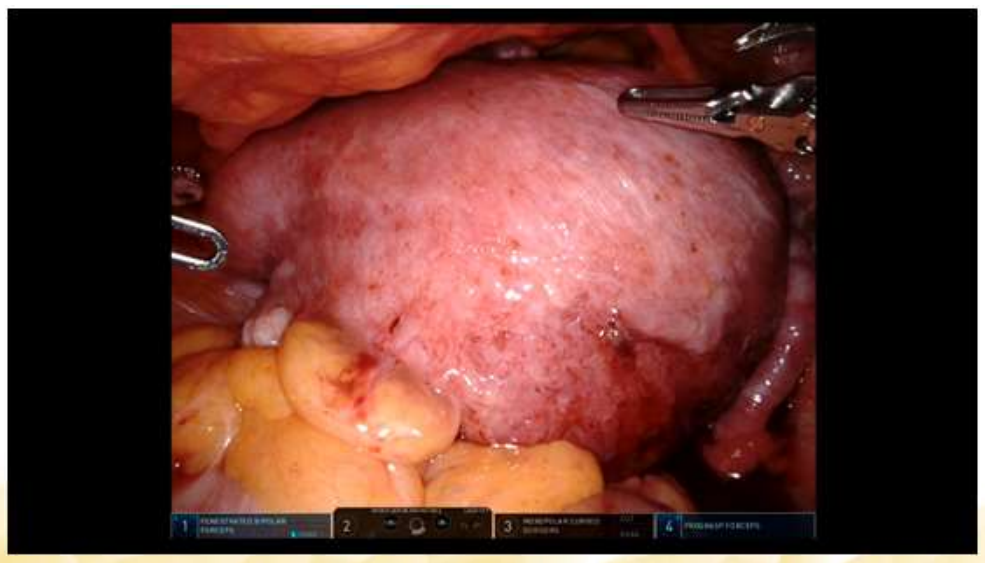

Wristed rigid instruments

OBLITERATED PATHOLOGY

CASE #3

33yo G0 with AUB, worsening dysmenorrhea.

- Exam: relatively mobile uterus, non-palpable adnexa
- MRI: left hematosalpinx and left ovarian endometrioma

- Procedure: Robotic LSO, myomectomy
- EBL: 200cc

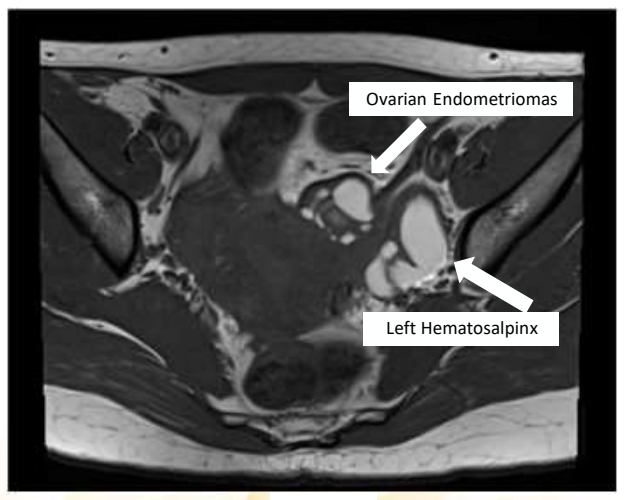
Ovarian Endometriomas
Left Hematosalpinx

T1 Axial

CASE #3: Left Hematosalpinx & Endometrioma

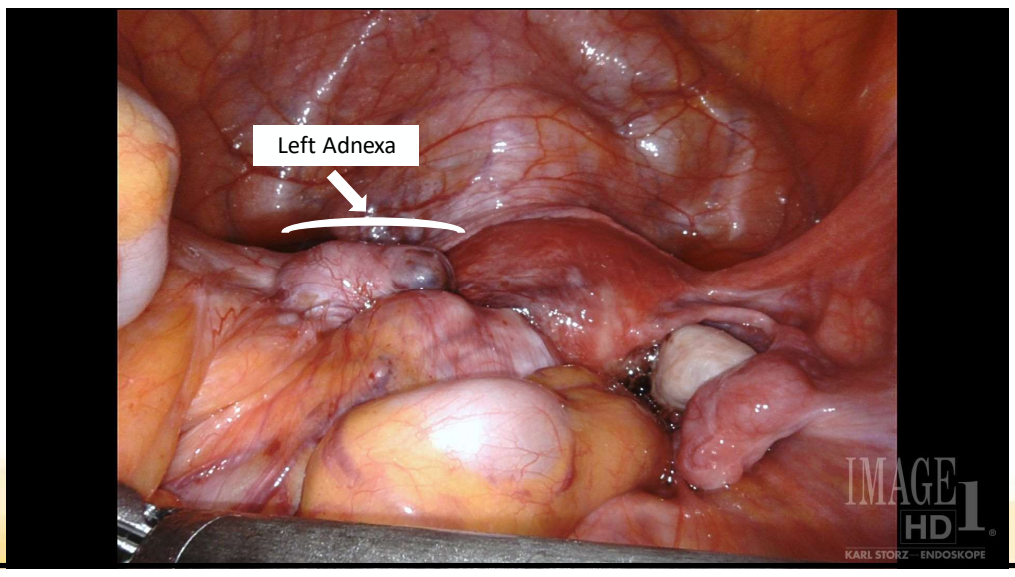
Left Adnexa
IMAGE1 HD
KARL STORZ ENDOSKOPE

CASE #4

48yo G3P0 s/p abdominal myomectomy x2, hsc myo x2, RFA with symptomatic fibroids.

- 2nd abd myo c/b severe adhesions with enterotomies requiring SB resection and reanastomosis.
- Exam: short torso, 18wk size uterus, relatively mobile

- Procedure: TRH, BS
- EBL: 175cc
- Specimen weight: 605g

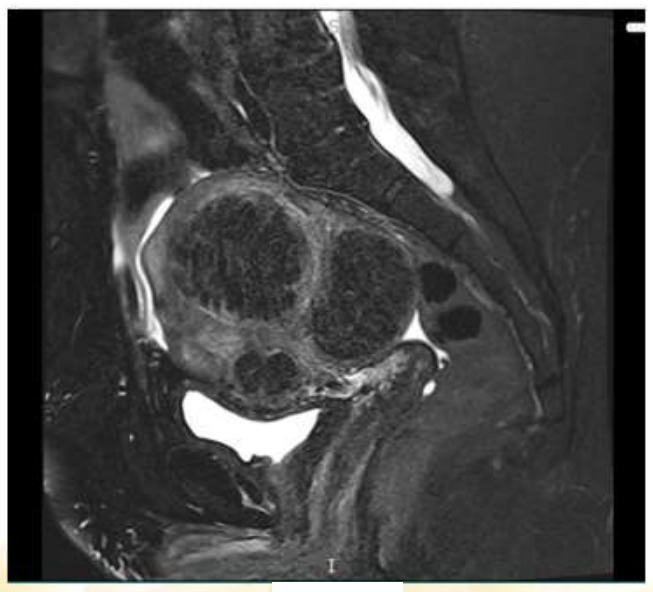

T2 Axial

CASE #4:

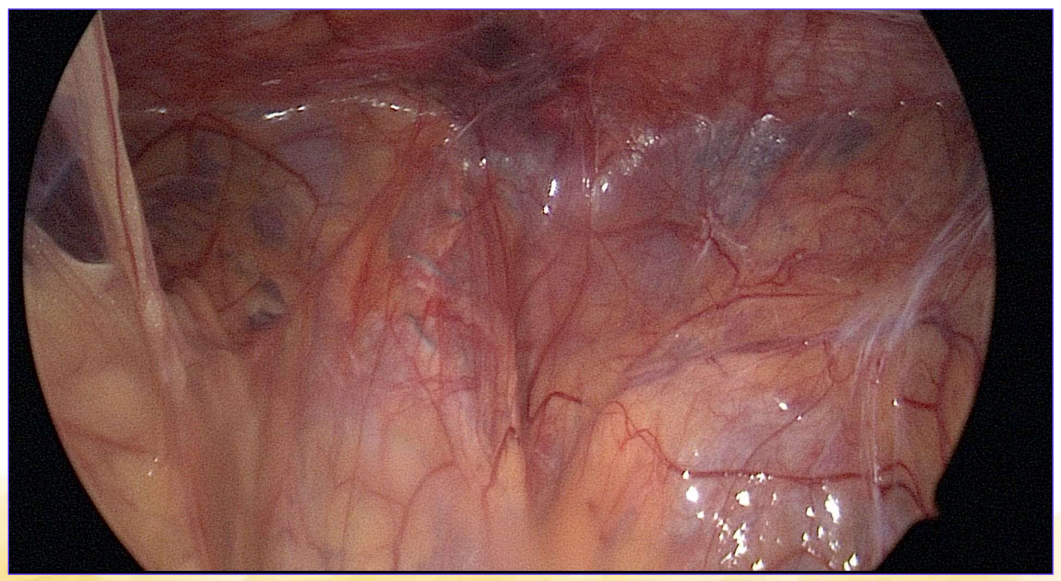

CASE #4

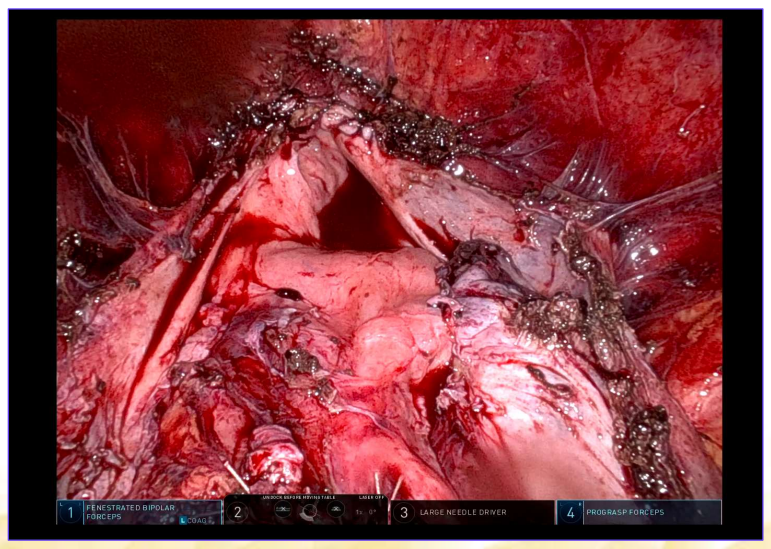

CASE #5

46yo G3P2 with worsening dysmenorrhea and 6cm right ovarian endometrioma.

- Exam: 8wk size retroverted uterus with restricted mobility, bilateral firm adnexal masses posterior to the uterus
- Procedure: TRH, BSO
- EBL: 100cc
- Specimen weight: 172g

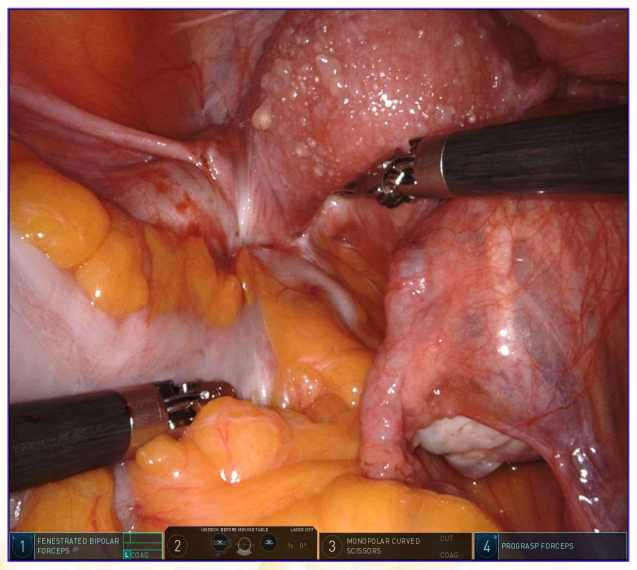

CASE #5:

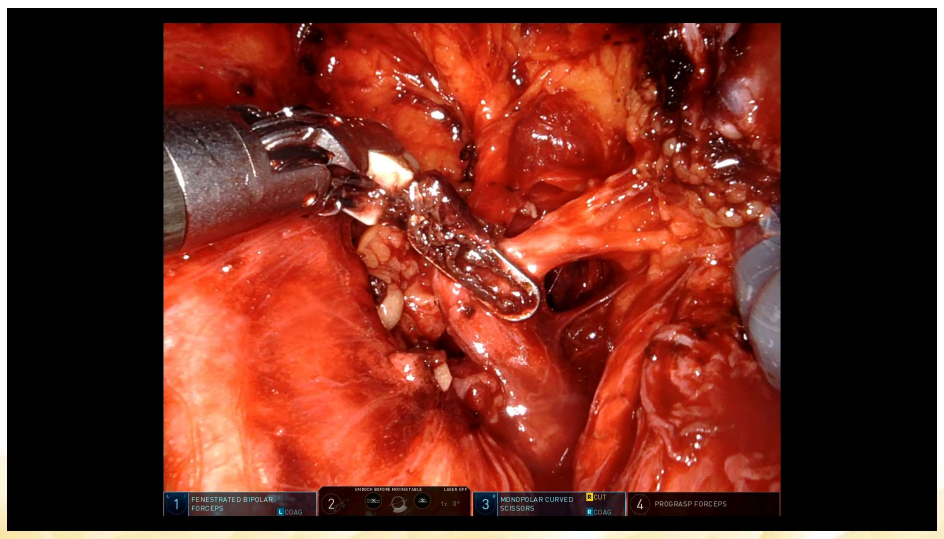

CASE #6:

35yo G3P2 with AUB, dysmenorrhea secondary to hematosalpinges, endometriomas and adenomyosis, s/p aborted laparoscopy, desires definitive treatment.

- Exam: 10wk size RV uterus, well suspended, minimally mobile
- Procedure: TRH, BSO
- EBL: 150cc
- Specimen weight: 184g

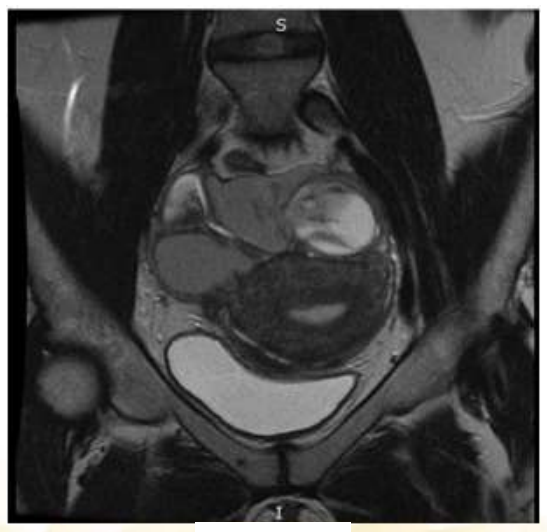

Coronal T2

CASE #6:

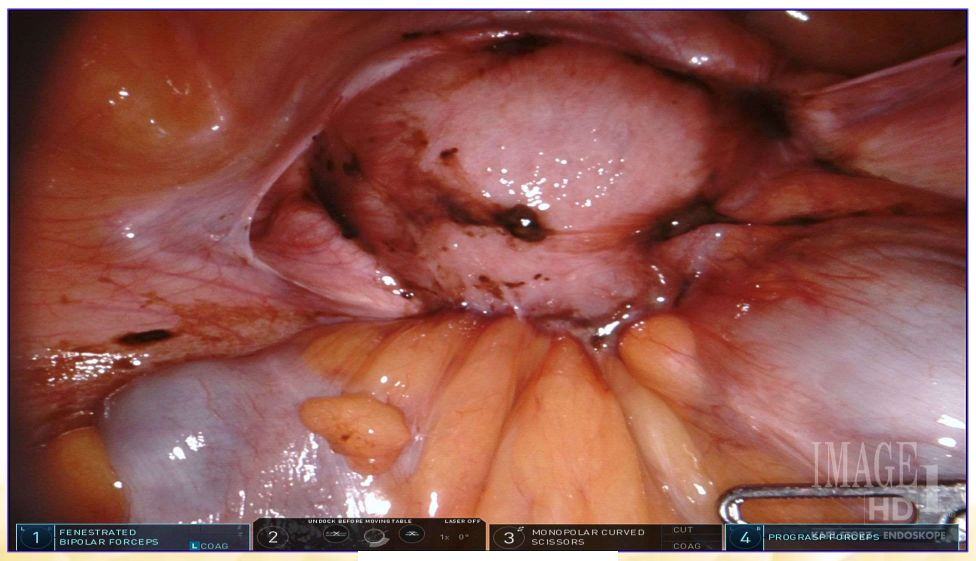

Global View of Pelvis

CASE 6

- VIDEO

What do these cases have to do with each other?

The Simple Secret…. Retract, Expose, Dissect

- Know anatomy
- Normalize Anatomy
  - Create normal
  - Go Retroperitoneal
  - Identify and dissect your deep pelvic spaces
- Circle the beast
- Don’t be dogmatic
- “Let me see what I can do”
- Use the robot to your benefit!

Benefits of the Robot for Complex Pathology

Complex Dissections
- 3-D visualization
- Wristed instruments
- Not assistant dependent (4th arm)
- Can get into & hold deep space dissections without fatigue

Large Pathology
- RIGID instrument shaft
- Wristed instruments
- Xi- easy port hopping
- Can maintain hold of a large uterus without fatigue

Improved visualization

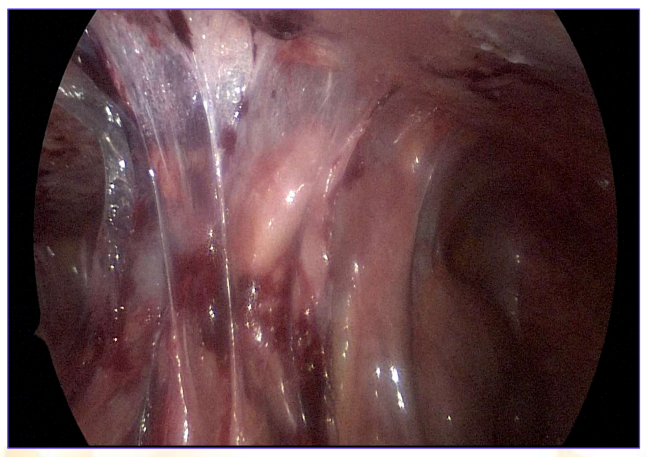
Laparoscopic View

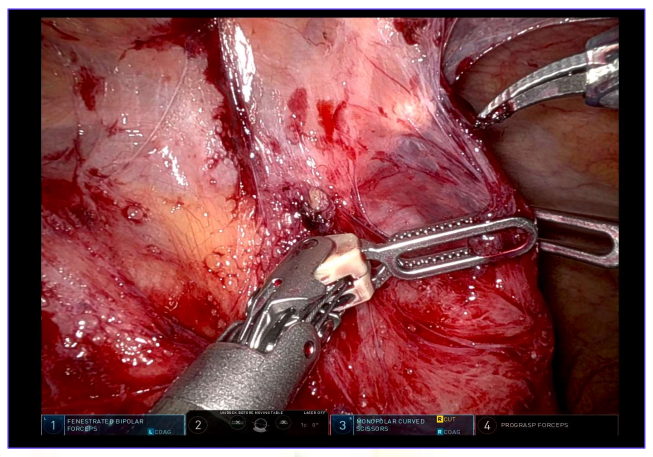
Robotic View

Why the Robot?

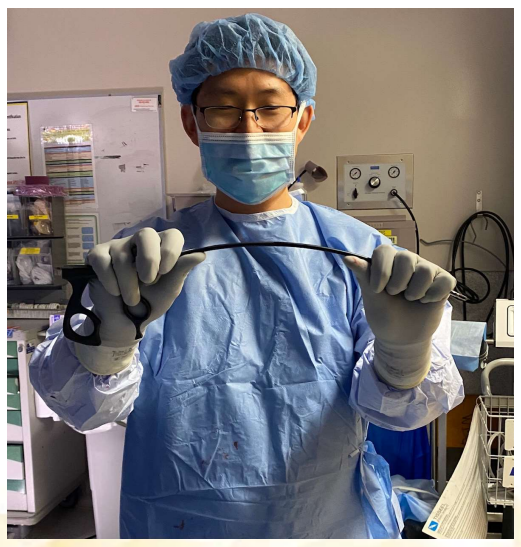
Bend of Laparoscopic Instrument

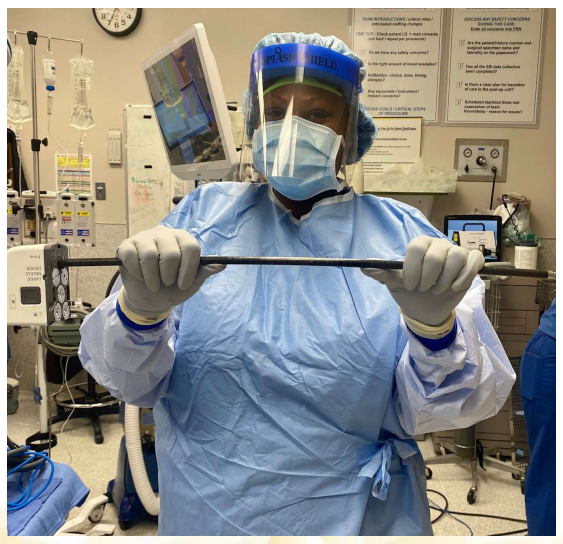
Bend of Robotic Instrument

Rigid Instruments

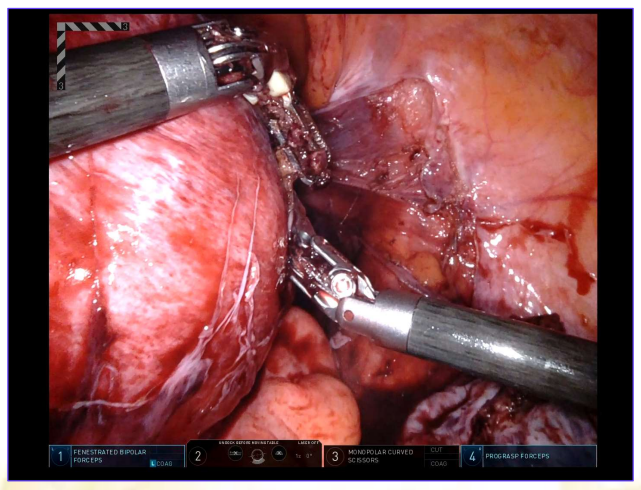
Human Manipulation

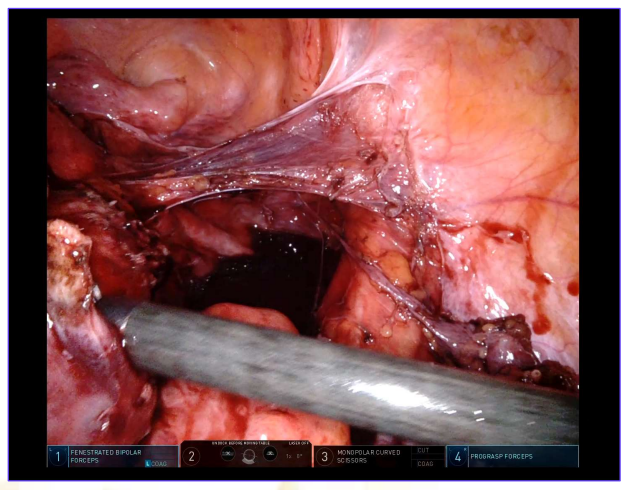
Robotic Manipulation

After 3 hrs of adhesiolysis…

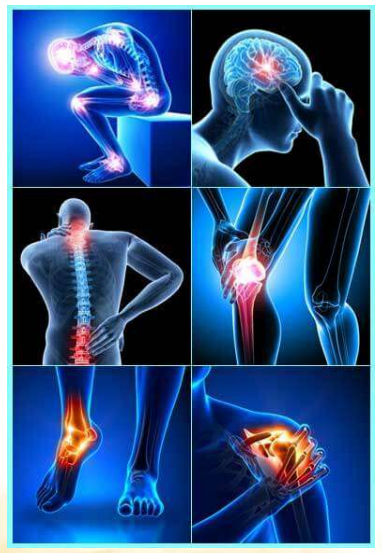
Laparoscopic fatigue

Robotic fatigue

References

1. Puntambekar S, Manchanda R. Surgical pelvic anatomy in gynecologic oncology. Inj J Gynecol Obstet. 2018; 143:86-92.

THANK YOU

AAGL 2022
51st GLOBAL CONGRESS ON MIGS
December 1-4, 2022 | Aurora, CO | congress.aagl.org

Transvaginal Complex Gynecologic Surgery

John B. Gebhart, MD, MS
Professor of OBGYN, Urology and Surgery
Division Chair – Urogynecology
Mayo Clinic
Rochester, MN, USA

Disclosure

- Advisory Board - UroCure
- Royalty: Elsevier, UpToDate

Learning objectives

- Share keys to “seeing” during vaginal surgery
- Tips and techniques for difficult transvaginal surgical situations

Focus for Today

- Visualization
- Anterior Entry
- Morcellation
- Advanced POP and it’s challenges

Set-up

- Exposure = visualization
  - Positioning
  - Adequate anesthesia
  - Lighting
  - Retraction
  - Surgeon

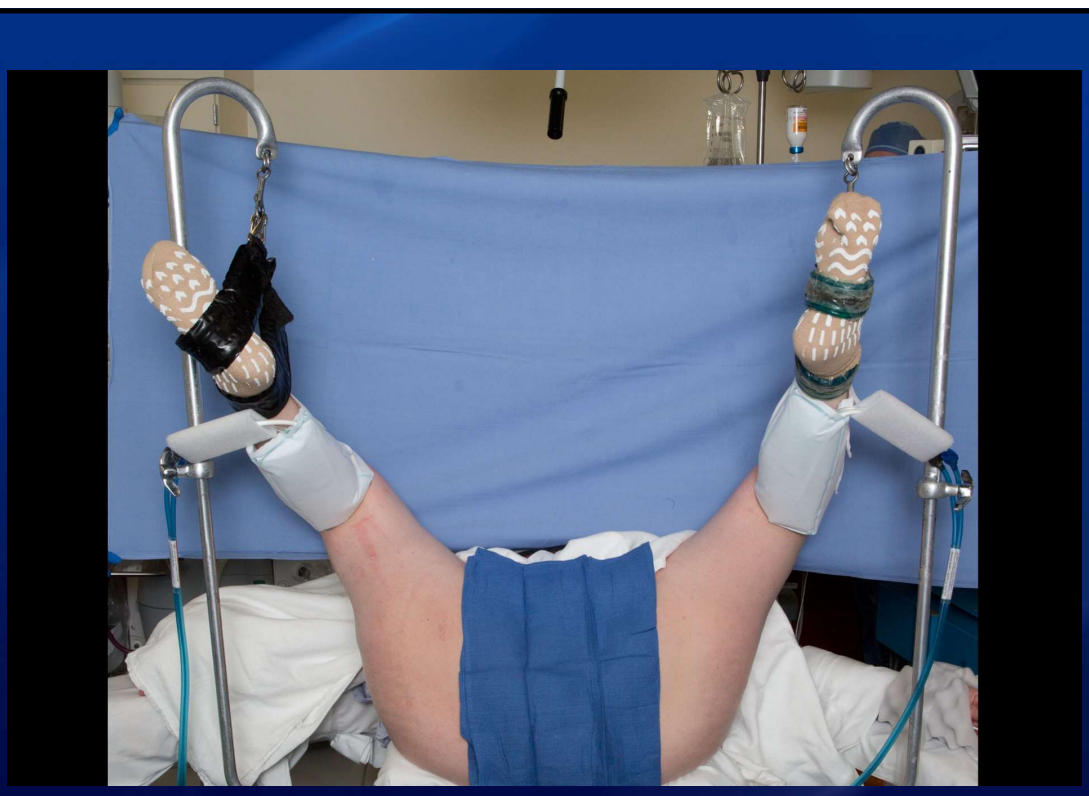

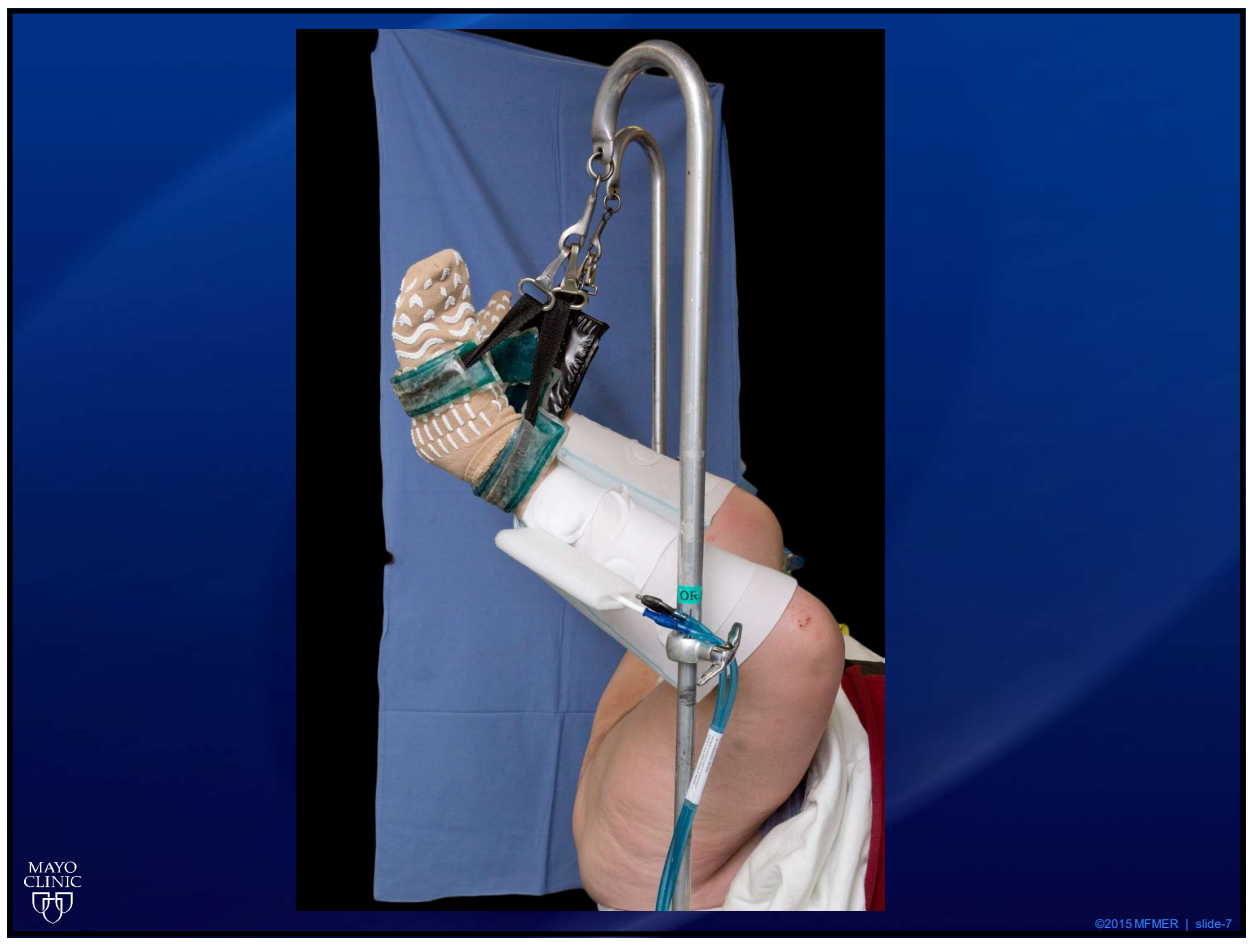

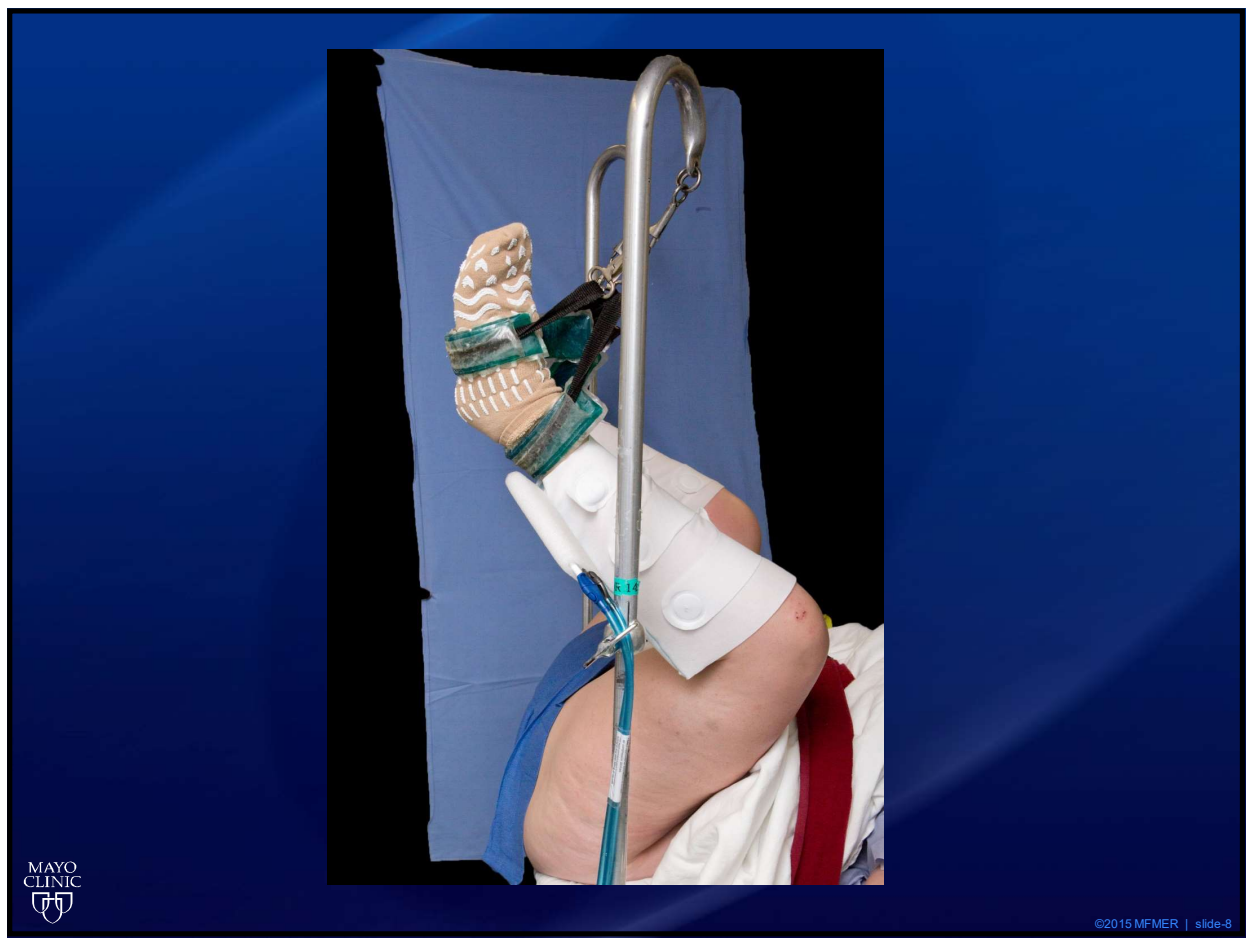

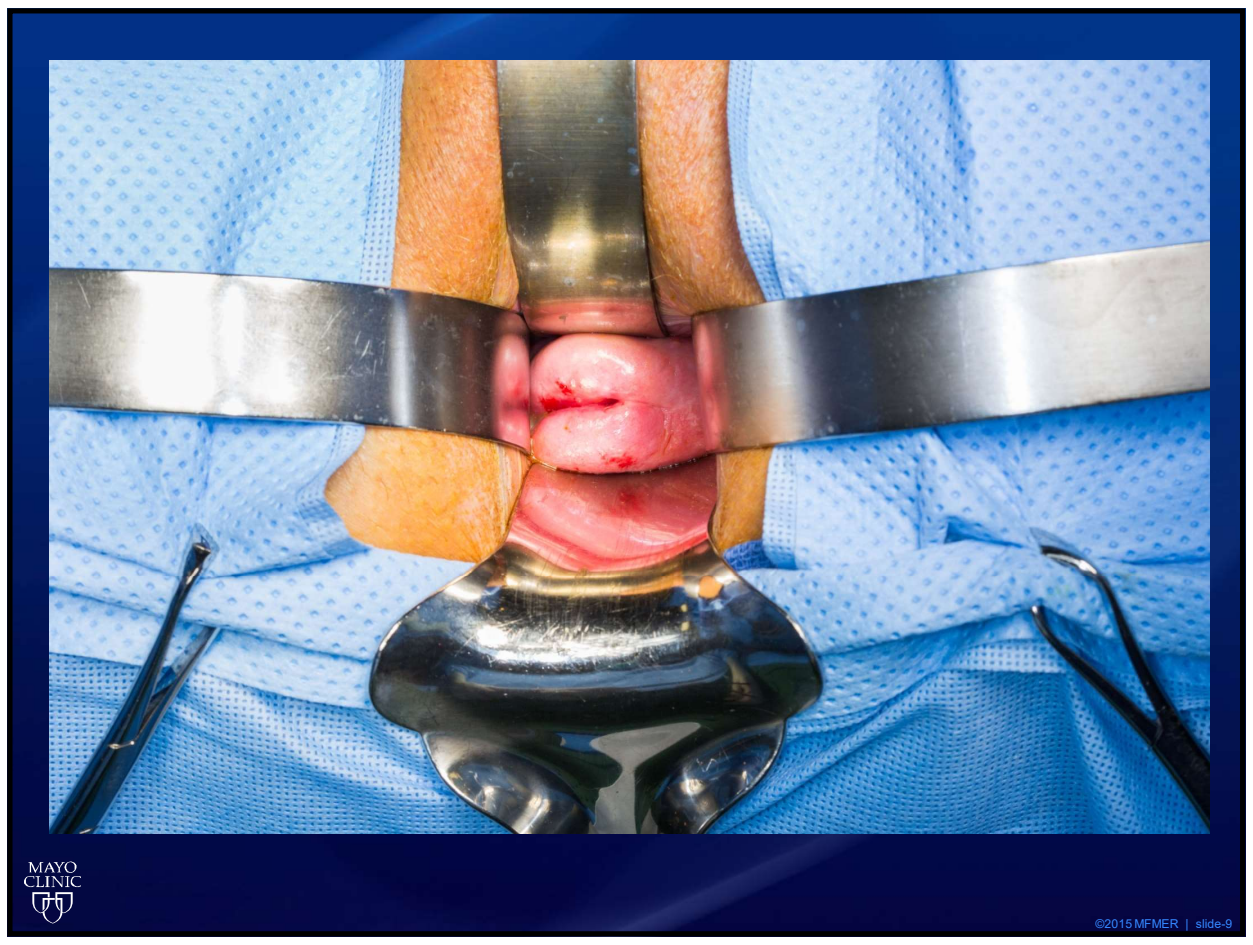

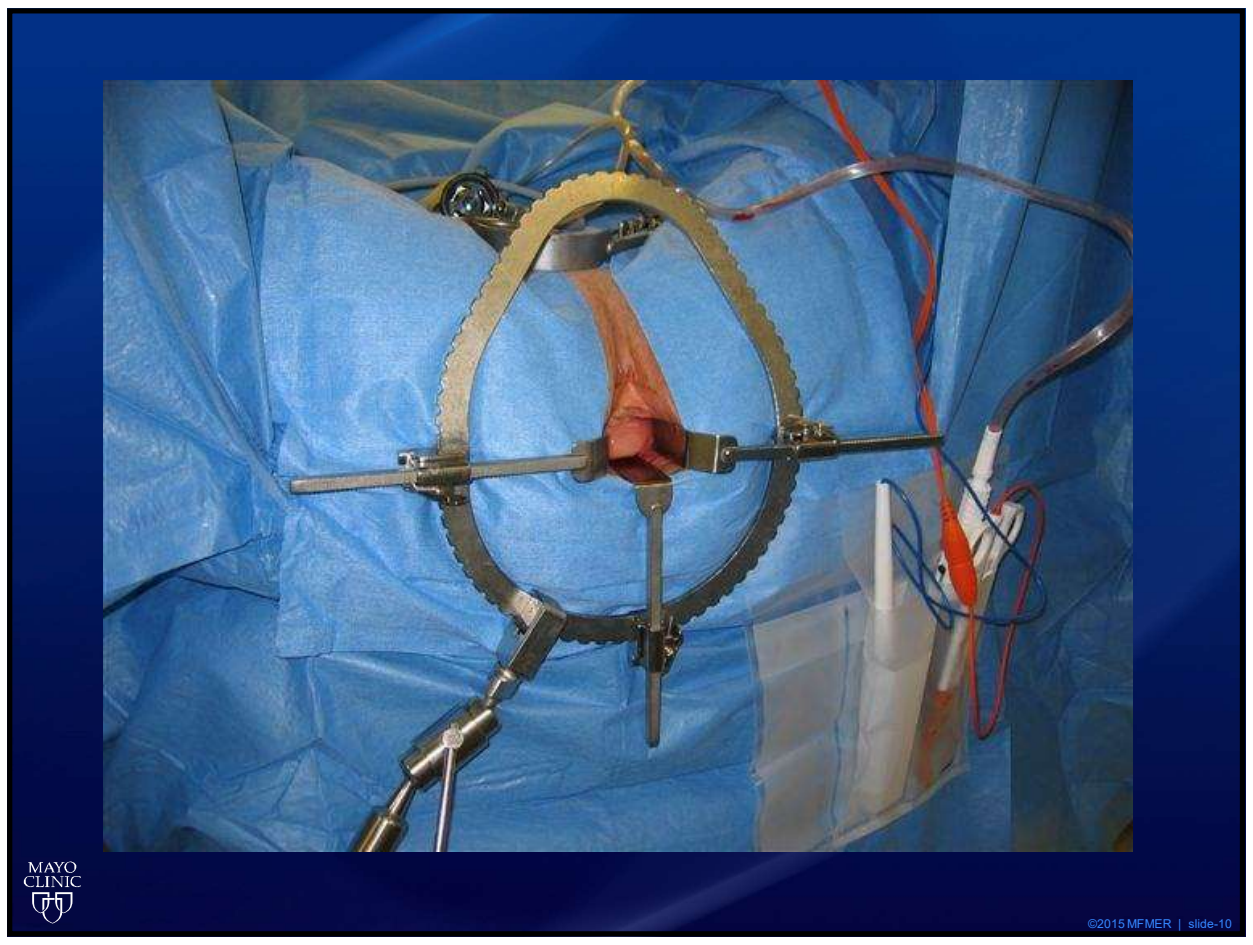

VH: Anterior Entry

- Bladder drainage
- Anterior or posterior entry first?
- Initial incision
- Stay in the midline
- Dissect along the uterus “hug the uterus”

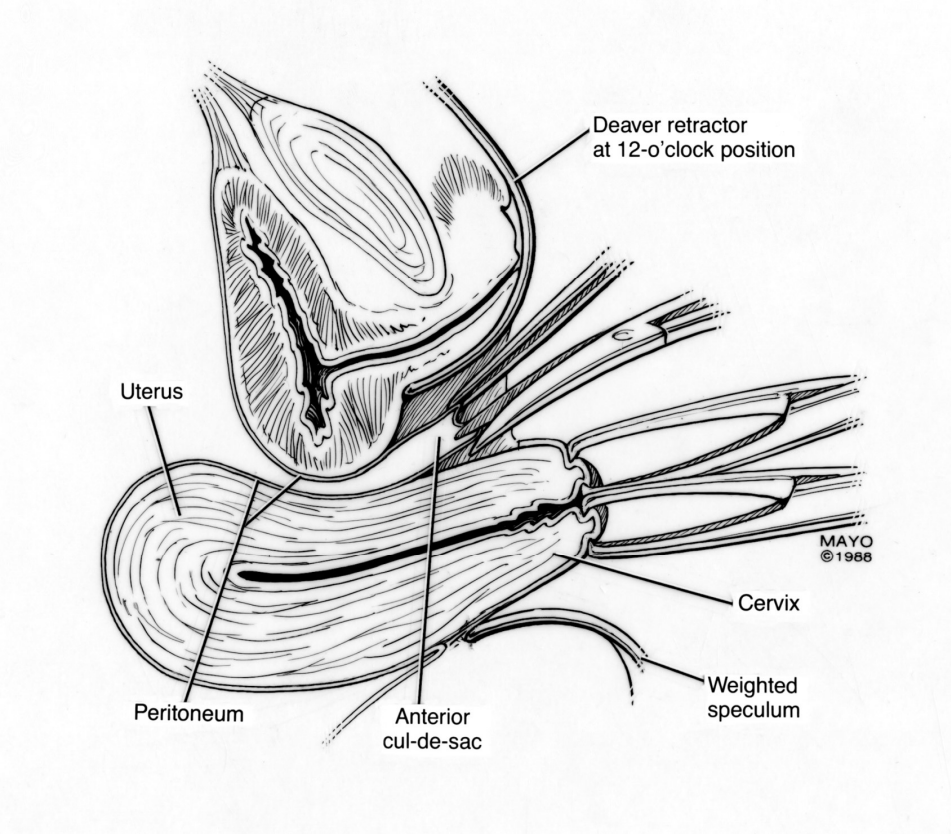
Deaver retractor
at 12-o'clock position
Uterus
MAYO
©1988
Cervix
Weighted
speculum
Peritoneum
Anterior
cul-de-sac

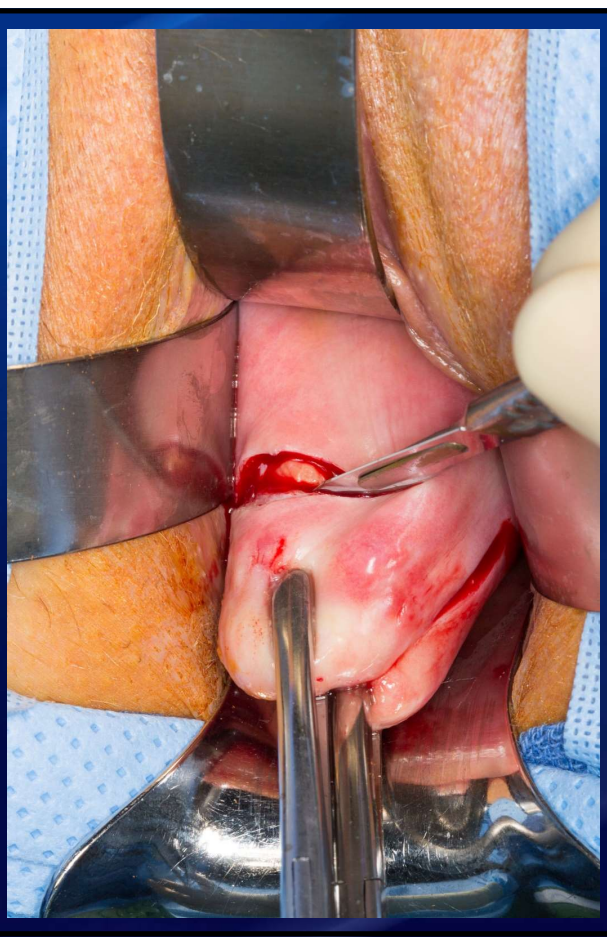

Difficult anterior entry videos

VH: Special circumstances

- Cervical elongation
- Morcellation
- Procidentia

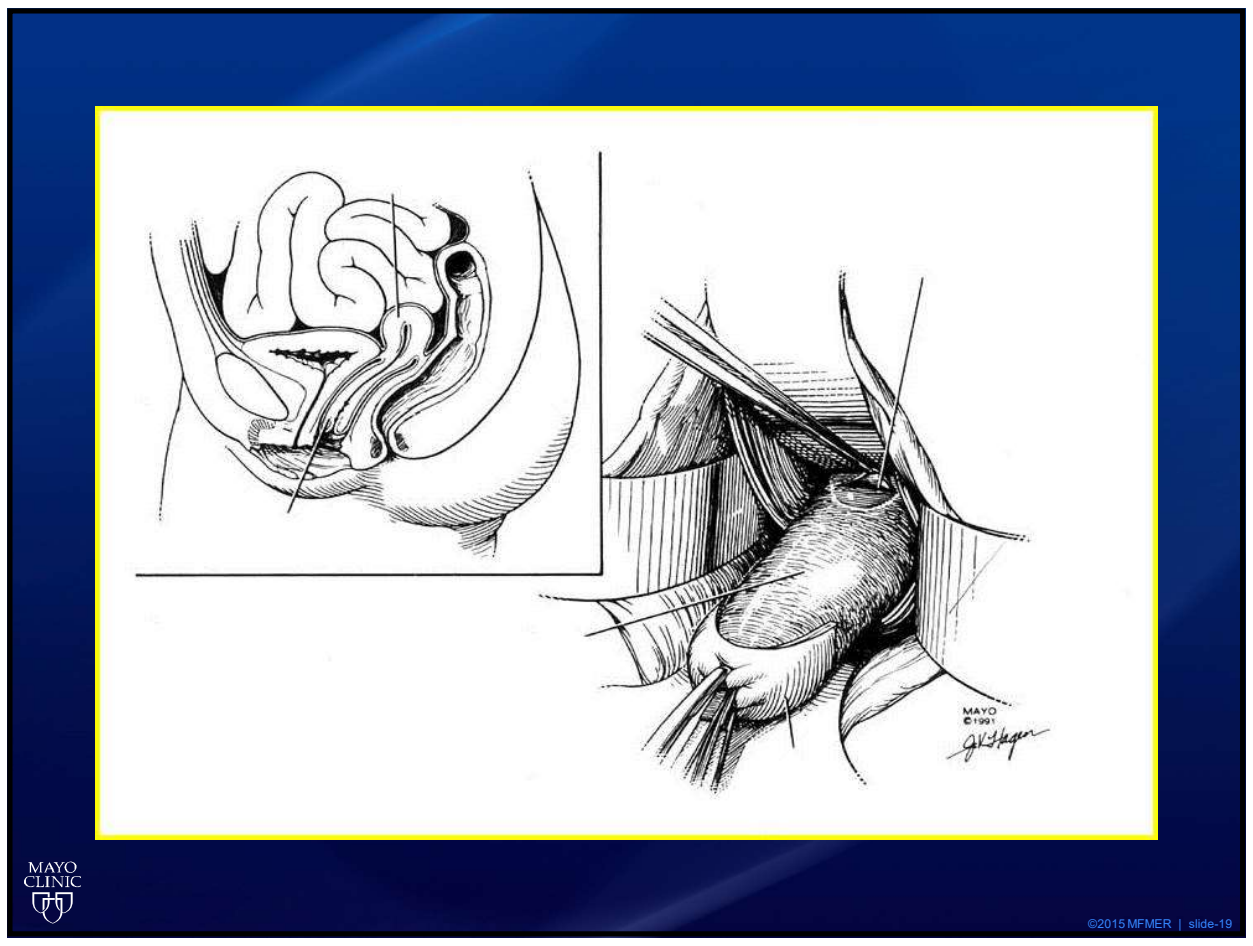

MAYO CLINIC

©2015 MFMER | slide-19

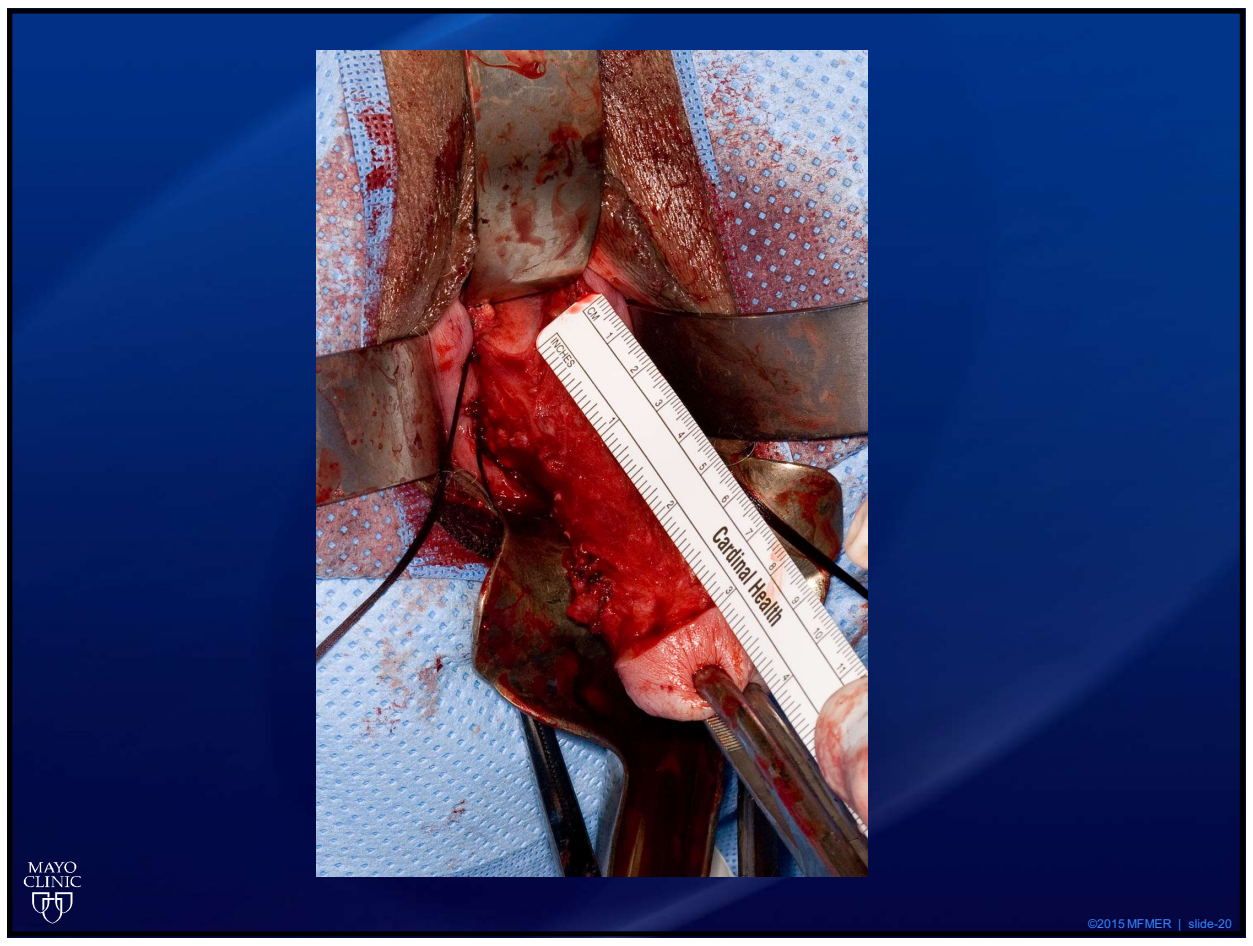
Cardinal Health

MAYO CLINIC

©2015 MFMER | slide-20

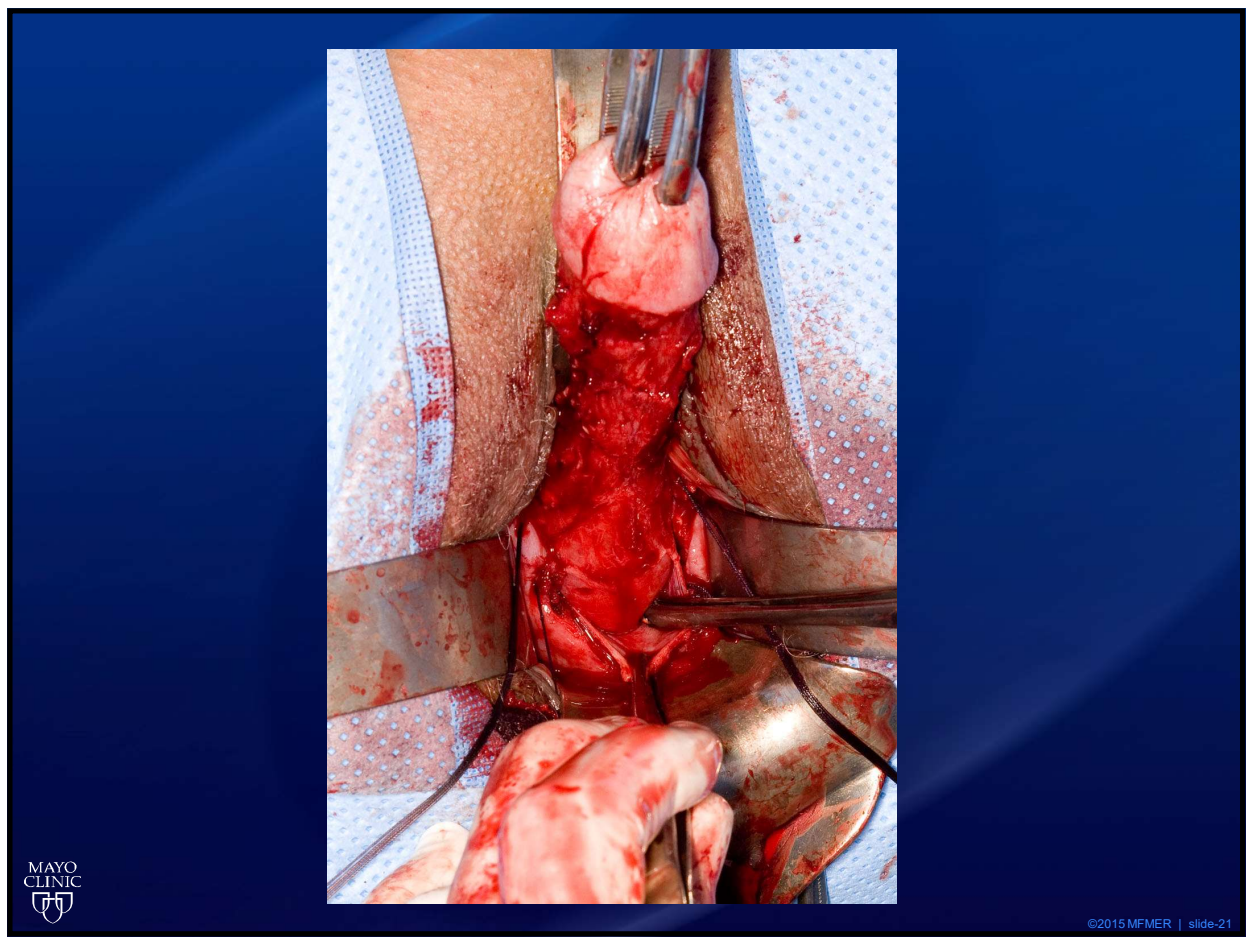

MAYO CLINIC

©2015 MFMER | slide-21

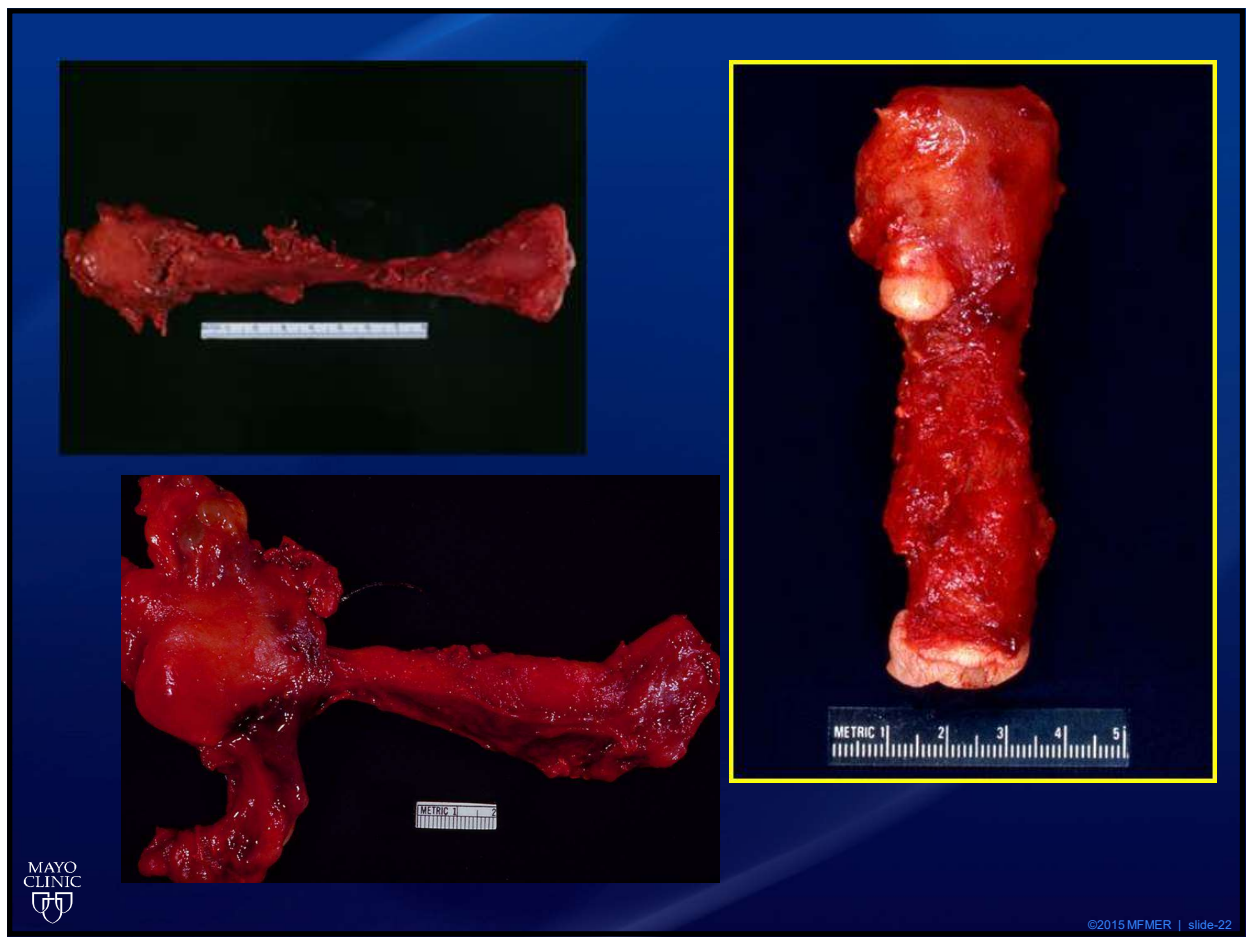
METRIC 1 2 3 4 5

MAYO CLINIC

©2015 MFMER | slide-22

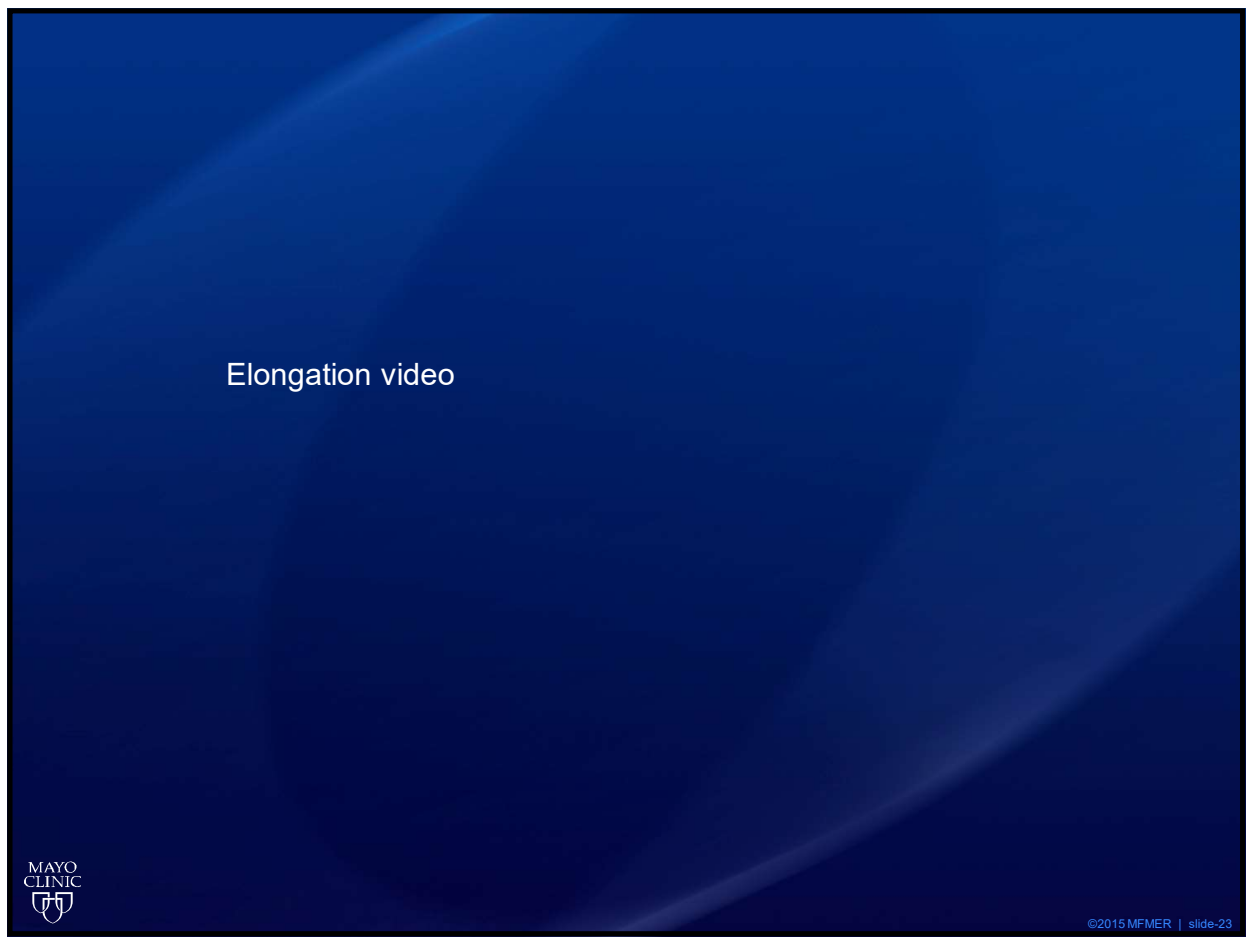

Elongation video

MAYO CLINIC

©2015 MFMER | slide-23

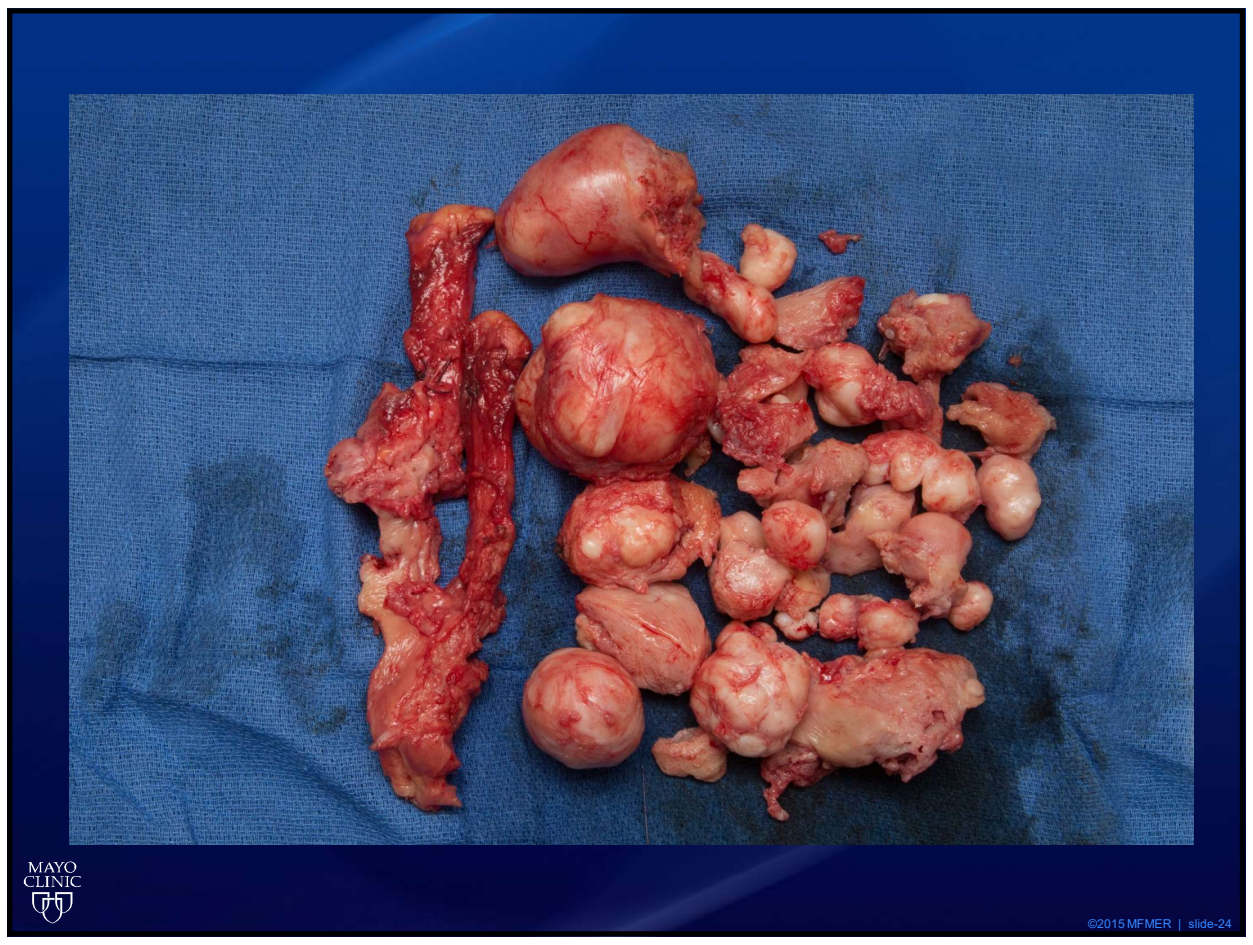

MAYO CLINIC

©2015 MFMER | slide-24

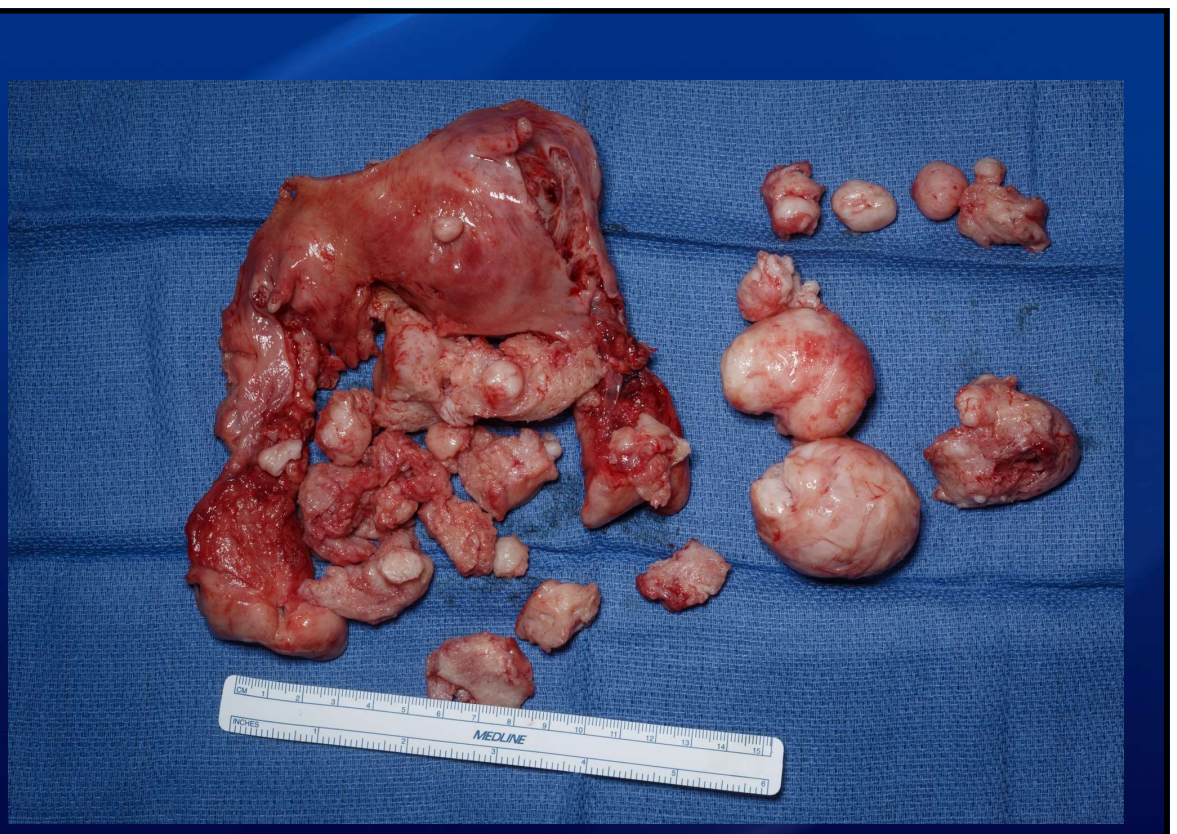

Morcellation video

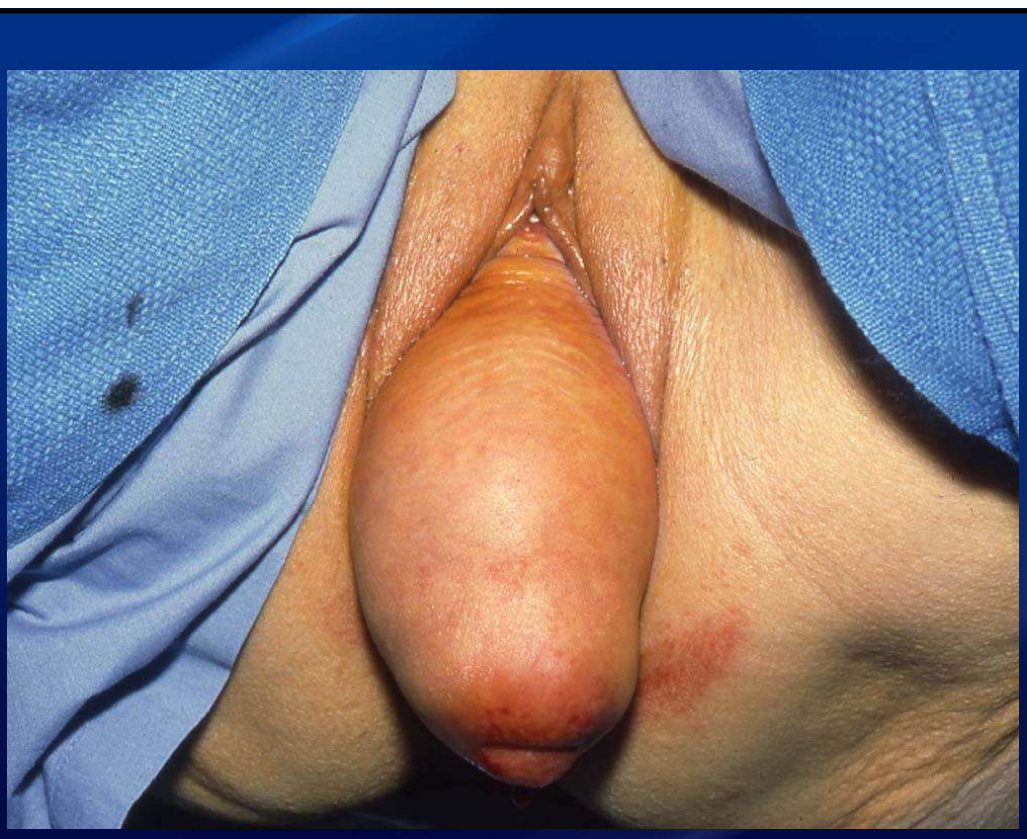

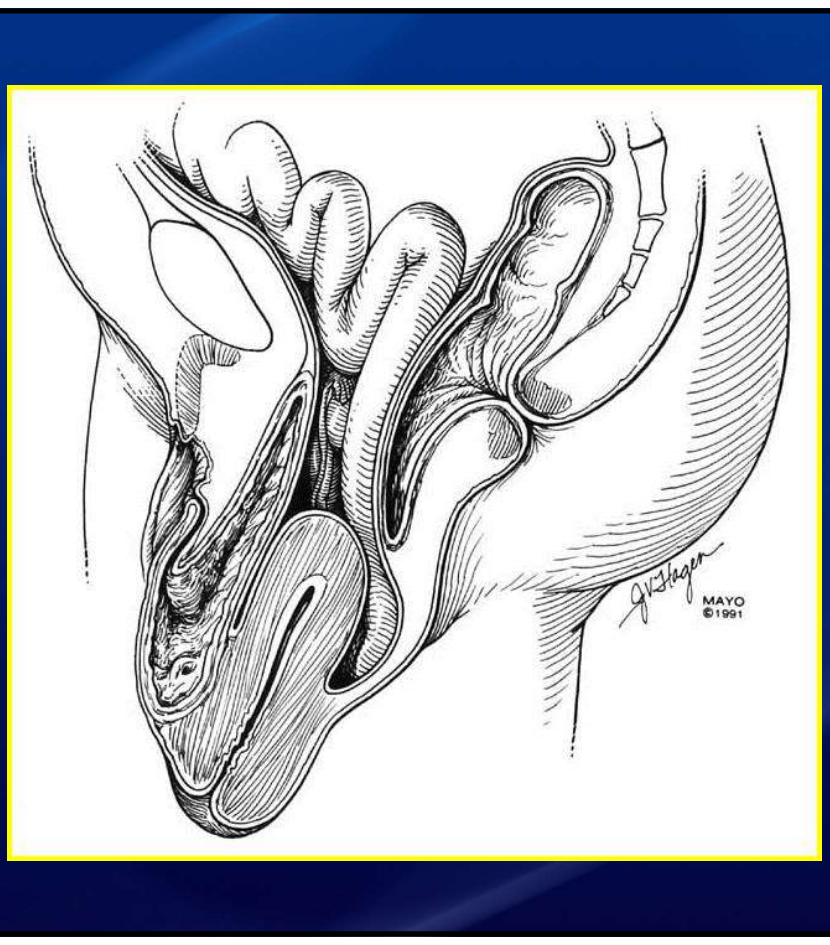

Ureter Video

Take Home Points

- Start with easy ones….
- Utilize techniques to “see” things better
- Recognize more challenging situations and learn techniques to help you overcome them.
- The more you do…..the more you can do!

MAYO CLINIC

Thank you

©2015 MFMER | slide-31

Single-site and vNOTES routues for Challenging Surgeries

Xiaoming Guan, MD, PhD
Professor
Division Chief & Fellowship Director of Minimally Invasive Gynecologic Surgery
Baylor College of Medicine, Houston, Texas

AAGL 2022
51st GLOBAL CONGRESS ON MIGS
December 1-4, 2022 | Aurora, CO | congress.aagl.org

Disclosure

- Speakers Bureau for Applied Medical

Objectives

- Articulating single-site and vNOTES surgery exposure techniques
- Elaborating the benefits and tips and tricks of single-site and vNOTES surgery
- Demonstrating the complex surgeries through single-site or vNOTES routes

Vertical Incision

INVERTED OMEGA

Semi Curved

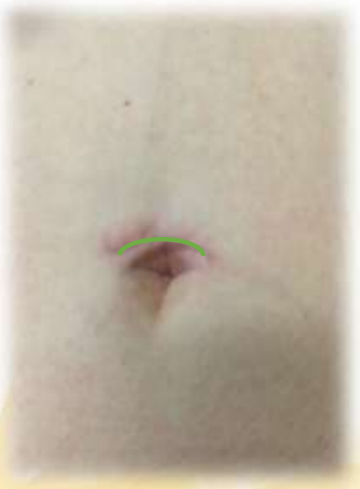

Rationale for SILS

	LESS	R-LESS	Multiport
Cosmesis	+++	+++	+
Ease of tissue retrivial	+++++	+++	+
Patient satisfactory	+++++	+++++	+++
Quality of life analysis	++	++	++
Standard instrumentations	++	+++	++++
Not violate natural orifices	+++++	+++++	+

Robotic Single Site Instruments

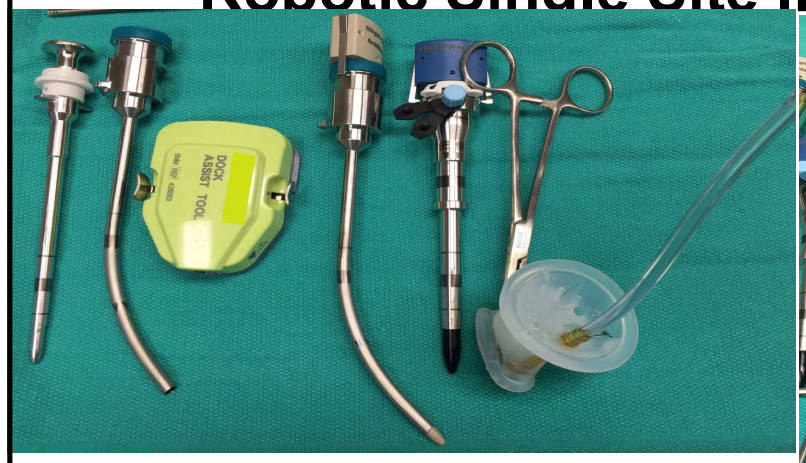

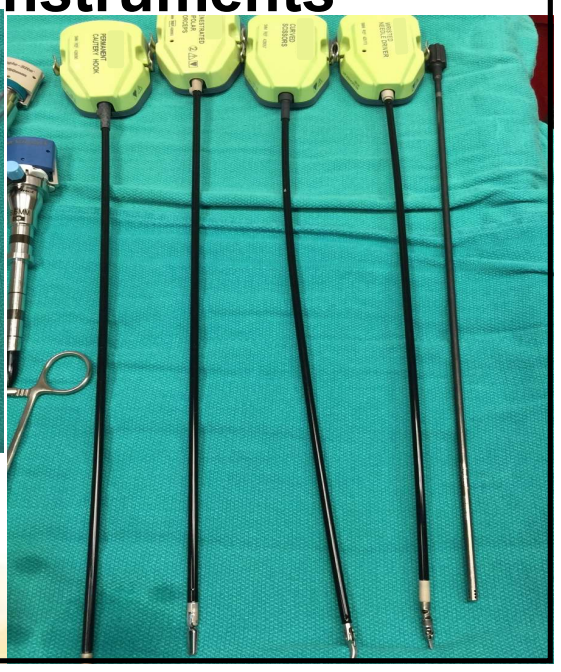

Robotic Xi system docking



Video will be played during lecture

Setup: Port placement

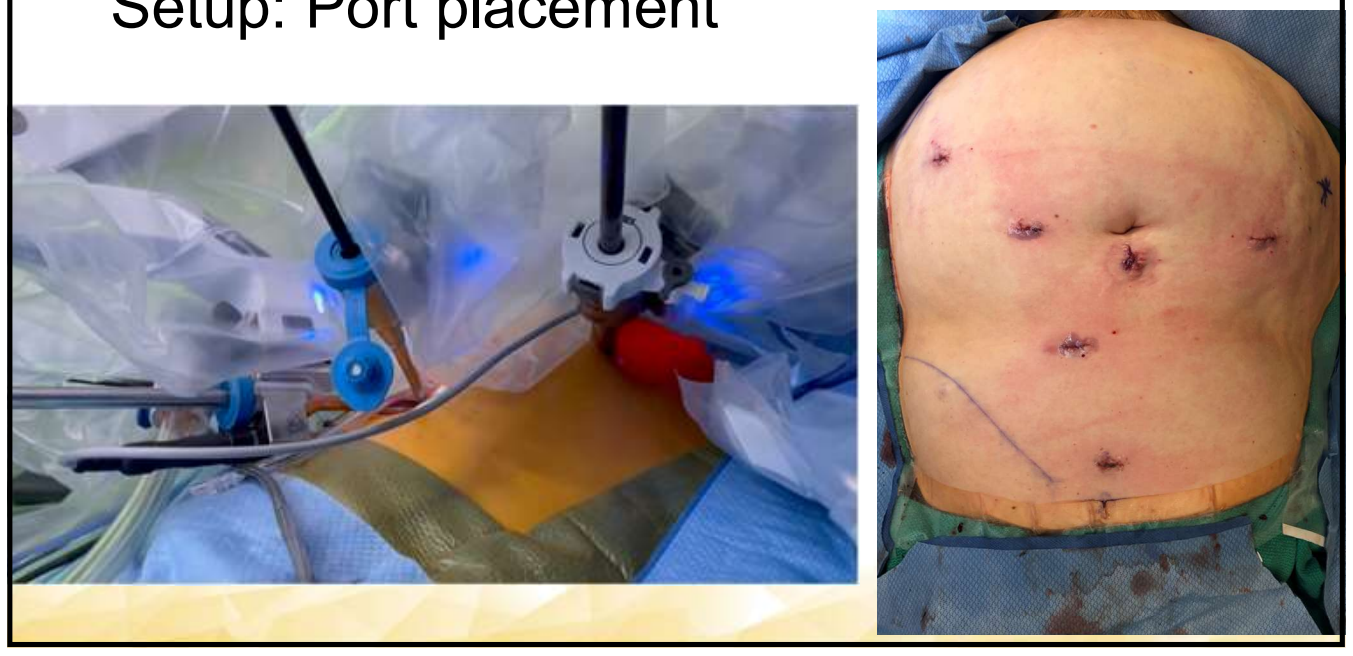

Exposure techniques from open surgery

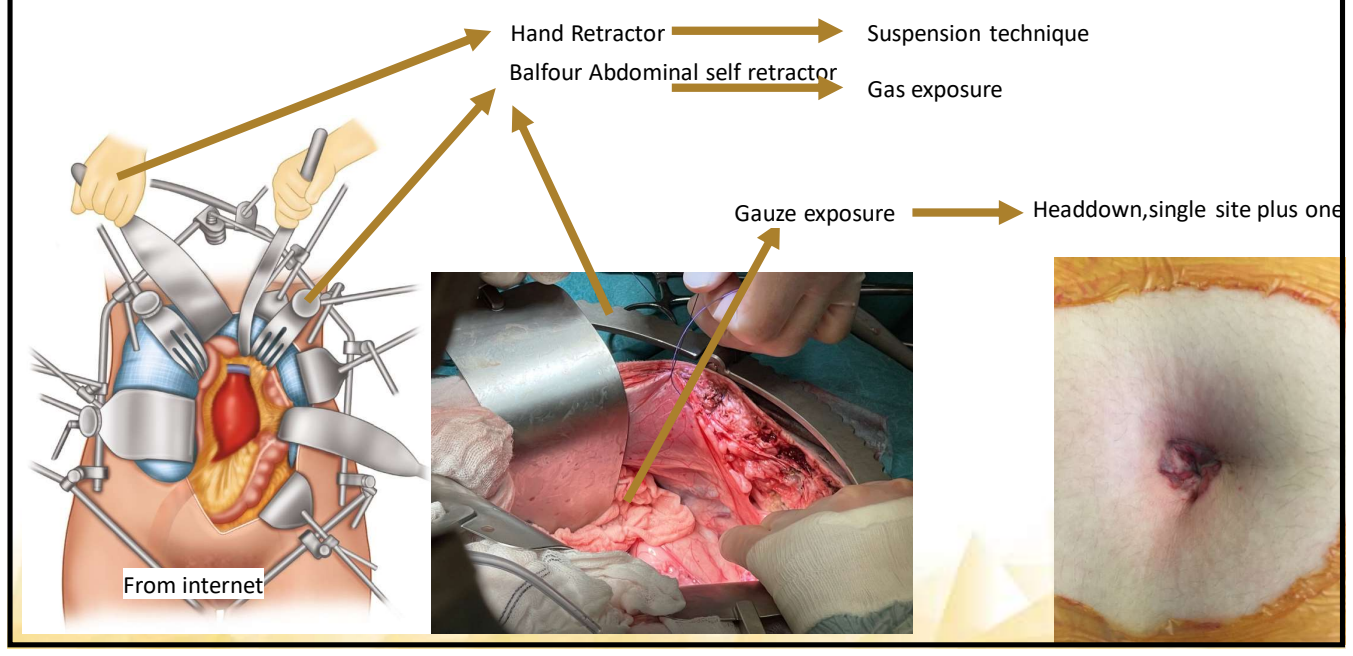

Hand Retractor → Suspension technique

Balfour Abdominal self retractor → Gas exposure

Gauze exposure → Headdown,single site plus one

From internet

Surgical exposure is the foundation of all surgery

- Single-site surgery has exposure issues due to limited help from assistants
- Surgical exposure includes
  1. Clear and smoke-free total surgical field of view
  2. Exposure of Local Surgical site – uterine manipulator, Head Down
  3. Consider a single-site plus one
- The surgeon should decide the exposure of the operation according to the difficulty of the operation

---



Single-site surgery gas control techniques

ALLY Uterine Positioning System®

Using needles and threads to remove the tissues that obstruct the field of vision, it can be fixed on the abdominal wall, which can make the operation more effective with less effort.

Video will be played during lecture

Video will be played during lecture

- Video will be played during lecture

Combined exposure

Single-site surgery exposure techniques

Zheng's 4C Suspension Method - Cross Suspension Method：

- When suspending the left uterine horn, select the needle insertion point about 10 cm above the right outer side of the umbilicus
- Then cross to the left uterine angle, suture the left adnexa and the left uterine cornor, pay attention to suture the free left teres ligament broken end inside, in order to increase the traction tension of the parametrium
- Use curved forceps and small gauze to fix the suspension wire on the abdominal wall outside the body after the needle is drawn
- Suspend the right uterine horn on the left anterior abdominal wall in the same way

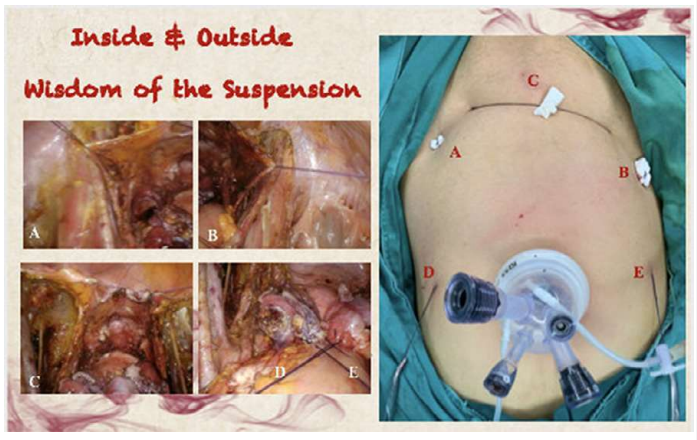

王卡娜,陈思敬,郑莹. 郑氏4C悬吊法在经脐单孔腹腔镜妇科恶性肿瘤手术中的应用[J]. 中华腔镜外科杂志（电子版）,2021,14(1):5-9.
Chen S, et al. J Minim Invasive Gynecol. 2020 Nov-Dec;27(7):1471-1472.

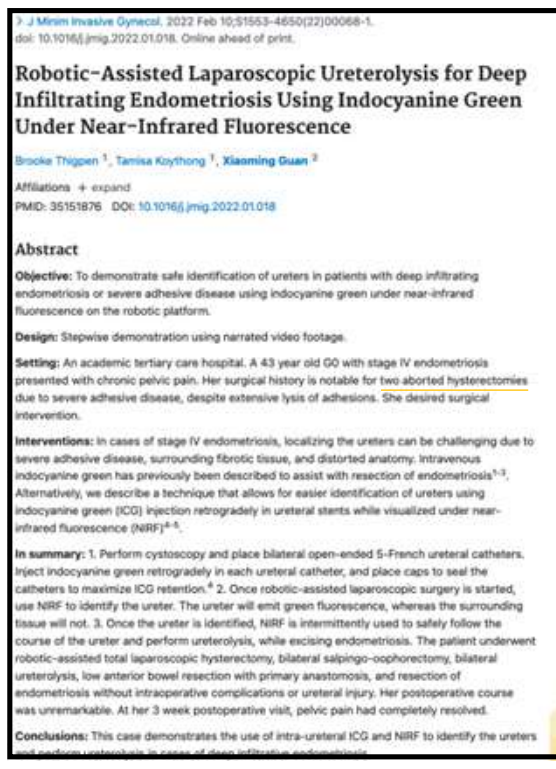

> J Minim Invasive Gynecol. 2022 Feb 10;S1553-4650(22)00068-1.
doi: 10.1016/j.jmig.2022.01.018. Online ahead of print.

Robotic-Assisted Laparoscopic Ureterolysis for Deep Infiltrating Endometriosis Using Indocyanine Green Under Near-Infrared Fluorescence

Brooke Thigpen [1], Tamisa Koythong [1], **Xiaoming Guan** [2]

Affiliations + expand

PMID: 35151876 DOI: 10.1016/j.jmig.2022.01.018

Abstract

Objective: To demonstrate safe identification of ureters in patients with deep infiltrating endometriosis or severe adhesive disease using indocyanine green under near-infrared fluorescence on the robotic platform.

Design: Stepwise demonstration using narrated video footage.

Setting: An academic tertiary care hospital. A 43 year old G0 with stage IV endometriosis presented with chronic pelvic pain. Her surgical history is notable for two aborted hysterectomies due to severe adhesive disease, despite extensive lysis of adhesions. She desired surgical intervention.

Interventions: In cases of stage IV endometriosis, localizing the ureters can be challenging due to severe adhesive disease, surrounding fibrotic tissue, and distorted anatomy. Intravenous indocyanine green has previously been described to assist with resection of endometriosis[1-3]. Alternatively, we describe a technique that allows for easier identification of ureters using indocyanine green (ICG) injection retrogradely in ureteral stents while visualized under near-infrared fluorescence (NIRF)[4-5].

In summary: 1. Perform cystoscopy and place bilateral open-ended 5-French ureteral catheters. Inject indocyanine green retrogradely in each ureteral catheter, and place caps to seal the catheters to maximize ICG retention.[4] 2. Once robotic-assisted laparoscopic surgery is started, use NIRF to identify the ureter. The ureter will emit green fluorescence, whereas the surrounding tissue will not. 3. Once the ureter is identified, NIRF is intermittently used to safely follow the course of the ureter and perform ureterolysis, while excising endometriosis. The patient underwent robotic-assisted total laparoscopic hysterectomy, bilateral salpingo-oophorectomy, bilateral ureterolysis, low anterior bowel resection with primary anastomosis, and resection of endometriosis without intraoperative complications or ureteral injury. Her postoperative course was unremarkable. At her 3 week postoperative visit, pelvic pain had completely resolved.

Conclusions: This case demonstrates the use of intra-ureteral ICG and NIRF to identify the ureters

Video will be played during lecture

- 40 yo, Asian, G1P2, Chronic pelvic pain for 25 years, CS for twin
- Rectal exam left posterior 4-5 cm nodule
- MRI: Bowel endometriosis with left pelvic nodule about 5 cm

Video will be played during lecture

- 35 yo, G1P1, stage IV endo and ovarian remnant
- Surgical history:
  - 2004, NSVD, complication of placenta retain, exploratory laparotomy
  - 2004,, TVH due to bleeding
  - 2004 Exploratory for bleeding,
  - 2017 exploratory LSO
  - 2018 RSO with appendix
  - **2019, SILS resection of endo,**
- Pain 8/10, most in her left pelvic
- MRI: There are proteinaceous/hemorrhagic masses in the pelvis. These are larger or new since the prior study. These may be related to endometriosis/endometriomas. Fluid collection in the pelvis anterior to the rectum is smaller.

Video will be played during lecture

Video will be played during lecture

Video will be played during lecture

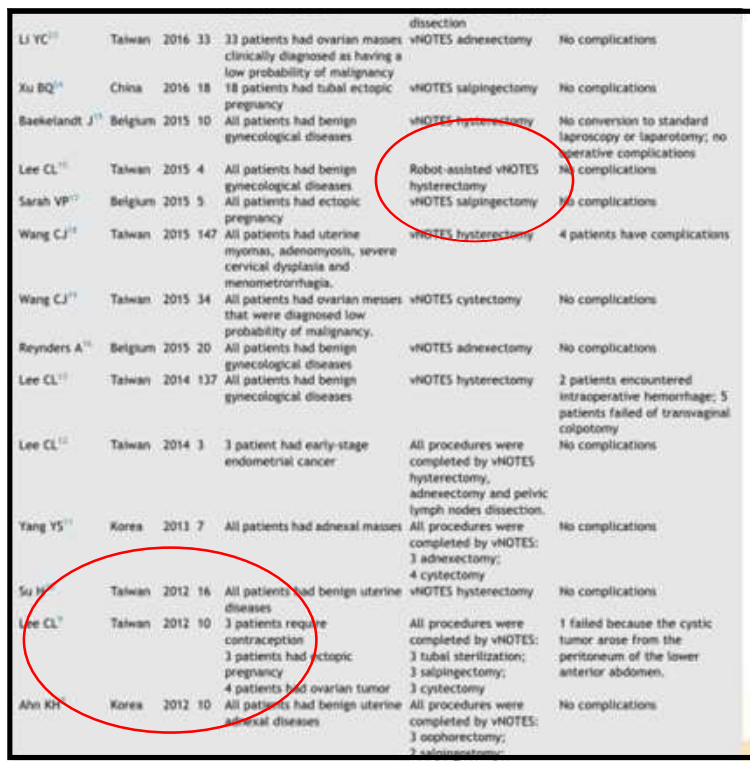

					dissection	
Li YC	Taiwan	2016	33	33 patients had ovarian masses clinically diagnosed as having a low probability of malignancy	vNOTES adnexectomy	No complications
Xu BQ	China	2016	18	18 patients had tubal ectopic pregnancy	vNOTES salpingectomy	No complications
Baekelandt J	Belgium	2015	10	All patients had benign gynecological diseases	vNOTES hysterectomy	No conversion to standard laproscopy or laparotomy; no operative complications
Lee CL	Taiwan	2015	4	All patients had benign gynecological diseases	Robot-assisted vNOTES hysterectomy	No complications
Sarah VP	Belgium	2015	5	All patients had ectopic pregnancy	vNOTES salpingectomy	No complications
Wang CJ	Taiwan	2015	147	All patients had uterine myomas, adenomyosis, severe cervical dysplasia and menometrorrhagia.	vNOTES hysterectomy	4 patients have complications
Wang CJ	Taiwan	2015	34	All patients had ovarian messes that were diagnosed low probability of malignancy.	vNOTES cystectomy	No complications
Reynders A	Belgium	2015	20	All patients had benign gynecological diseases	vNOTES adnexectomy	No complications
Lee CL	Taiwan	2014	137	All patients had benign gynecological diseases	vNOTES hysterectomy	2 patients encountered intraoperative hemorrhage; 5 patients failed of transvaginal colpotomy
Lee CL	Taiwan	2014	3	3 patient had early-stage endometrial cancer	All procedures were completed by vNOTES hysterectomy, adnexectomy and pelvic lymph nodes dissection.	No complications
Yang YS	Korea	2013	7	All patients had adnexal masses	All procedures were completed by vNOTES: 3 adnexectomy; 4 cystectomy	No complications
Su H	Taiwan	2012	16	All patients had benign uterine diseases	vNOTES hysterectomy	No complications
Lee CL	Taiwan	2012	10	3 patients require contraception 3 patients had ectopic pregnancy 4 patients had ovarian tumor	All procedures were completed by vNOTES: 3 tubal sterilization; 3 salpingectomy; 3 cystectomy	1 failed because the cystic tumor arose from the peritoneum of the lower anterior abdomen.
Ahn KH	Korea	2012	10	All patients had benign uterine adnexal diseases	All procedures were completed by vNOTES: 3 oophorectomy;	No complications

Li CB, Hua KQ. Transvaginal natural orifice transluminal endoscopic surgery (vNOTES) in gynecologic surgeries: A systematic review. Asian J Surg. 2020 Jan;43(1):44-51. doi: 10.1016/j.asjsur.2019.07.014. Epub 2019 Aug 20. PMID: 31444108.

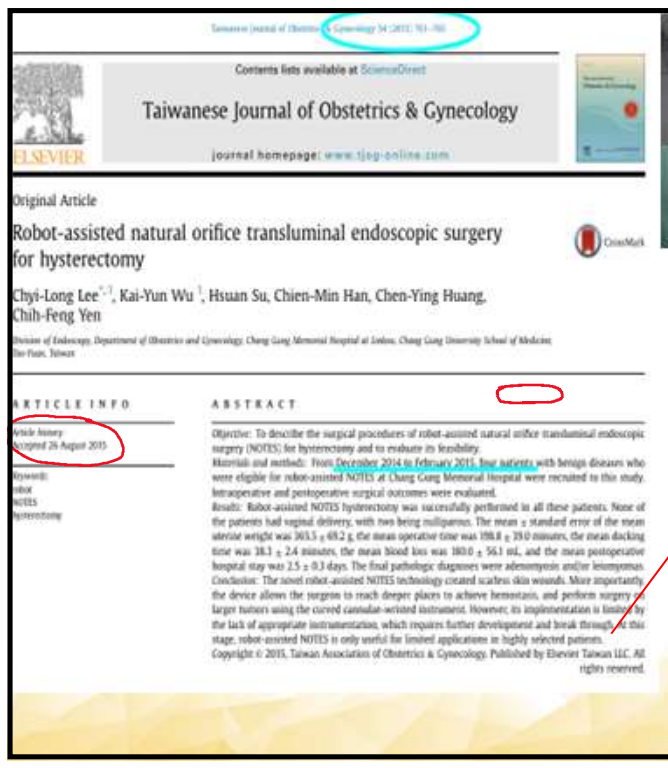

Taiwanese Journal of Obstetrics & Gynecology 54 (2015) 761–765

Contents lists available at ScienceDirect

Taiwanese Journal of Obstetrics & Gynecology

journal homepage: www.tjog-online.com

Original Article

Robot-assisted natural orifice transluminal endoscopic surgery for hysterectomy

Chyi-Long Lee, Kai-Yun Wu, Hsuan Su, Chien-Min Han, Chen-Ying Huang, Chih-Feng Yen

Division of Endoscopy, Department of Obstetrics and Gynecology, Chang Gung Memorial Hospital at Linkou, Chang Gung University School of Medicine, Tao-Yuan, Taiwan

ARTICLE INFO

Article history:
Accepted 26 August 2015

Keywords:
robot
NOTES
hysterectomy

ABSTRACT

Objective: To describe the surgical procedures of robot-assisted natural orifice transluminal endoscopic surgery (NOTES) for hysterectomy and to evaluate its feasibility.
Materials and methods: From December 2014 to February 2015, four patients with benign diseases who were eligible for robot-assisted NOTES at Chang Gung Memorial Hospital were recruited to this study. Intraoperative and postoperative surgical outcomes were evaluated.
Results: Robot-assisted NOTES hysterectomy was successfully performed in all these patients. None of the patients had vaginal delivery, with two being nulliparous. The mean ± standard error of the mean uterine weight was 303.5 ± 69.2 g, the mean operative time was 198.8 ± 39.0 minutes, the mean docking time was 38.3 ± 2.4 minutes, the mean blood loss was 180.0 ± 56.1 mL, and the mean postoperative hospital stay was 2.5 ± 0.3 days. The final pathologic diagnoses were adenomyosis and/or leiomyomas.
Conclusion: The novel robot-assisted NOTES technology created scarless skin wounds. More importantly the device allows the surgeon to reach deeper places to achieve hemostasis, and perform surgery on larger tumors using the curved cannulae-wristed instrument. However, its implementation is limited by the lack of appropriate instrumentation, which requires further development and break through. At this stage, robot-assisted NOTES is only useful for limited applications in highly selected patients.
Copyright © 2015, Taiwan Association of Obstetrics & Gynecology. Published by Elsevier Taiwan LLC. All rights reserved.

At this stage, robot-assited NOTES is only useful for limited applications in highly selected patients

Early literature :Robotic NOTES gynecologic surgery

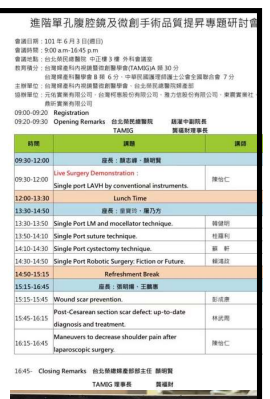

進階單孔腹腔鏡及微創手術品質提昇專題研討會

會議日期：101 年 6 月 3 日(週日)
會議時間：9:00 a.m-16:45 p.m

09:00-09:20 Registration
09:20-09:30 Opening Remarks

09:30-12:00		
09:30-12:00	Live Surgery Demonstration : Single port LAVH by conventional instruments.	[illegible]
12:00-13:30	Lunch Time	
13:30-14:50		
13:30-13:50	Single Port LM and morcellator technique.	[illegible]
13:50-14:10	Single Port suture technique.	[illegible]
14:10-14:30	Single Port cystectomy technique.	[illegible]
14:30-14:50	Single Port Robotic Surgery: Fiction or Future.	[illegible]
14:50-15:15	Refreshment Break	
15:15-16:45		
15:15-15:45	Wound scar prevention.	[illegible]
15:45-16:15	Post-Cesarean section scar defect: up-to-date diagnosis and treatment.	[illegible]
16:15-16:45	Maneuvers to decrease shoulder pain after laparoscopic surgery.	[illegible]

16:45- Closing Remarks

Miscellaneous

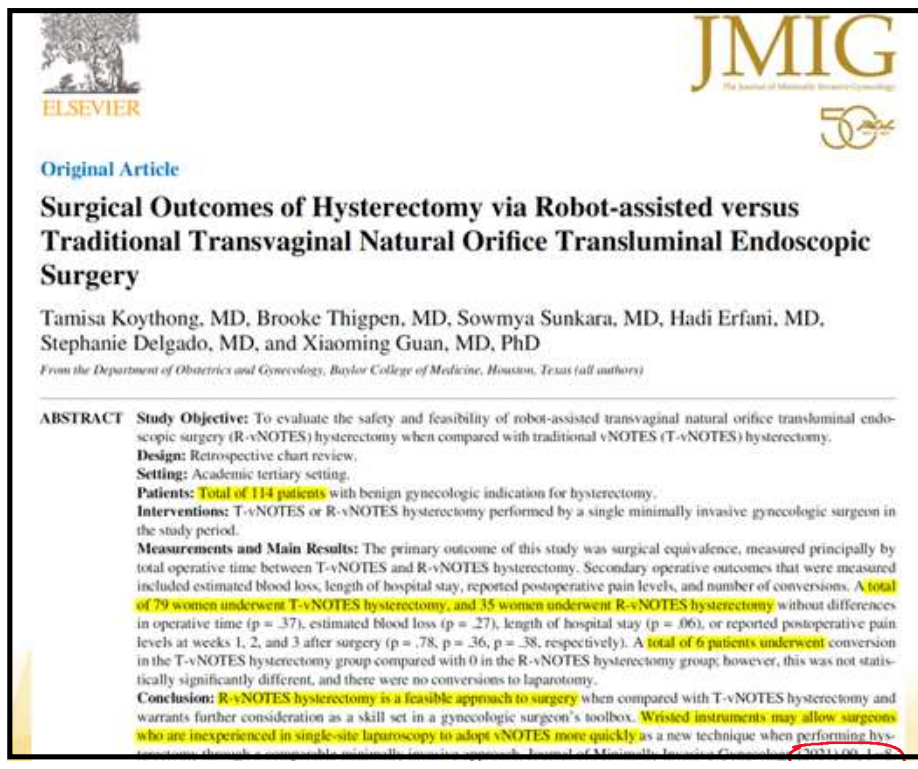

ELSEVIER

JMIG

Original Article

Surgical Outcomes of Hysterectomy via Robot-assisted versus Traditional Transvaginal Natural Orifice Transluminal Endoscopic Surgery

Tamisa Koythong, MD, Brooke Thigpen, MD, Sowmya Sunkara, MD, Hadi Erfani, MD, Stephanie Delgado, MD, and Xiaoming Guan, MD, PhD

From the Department of Obstetrics and Gynecology, Baylor College of Medicine, Houston, Texas (all authors)

ABSTRACT **Study Objective:** To evaluate the safety and feasibility of robot-assisted transvaginal natural orifice transluminal endoscopic surgery (R-vNOTES) hysterectomy when compared with traditional vNOTES (T-vNOTES) hysterectomy.
Design: Retrospective chart review.
Setting: Academic tertiary setting.
Patients: Total of 114 patients with benign gynecologic indication for hysterectomy.
Interventions: T-vNOTES or R-vNOTES hysterectomy performed by a single minimally invasive gynecologic surgeon in the study period.
Measurements and Main Results: The primary outcome of this study was surgical equivalence, measured principally by total operative time between T-vNOTES and R-vNOTES hysterectomy. Secondary operative outcomes that were measured included estimated blood loss, length of hospital stay, reported postoperative pain levels, and number of conversions. A total of 79 women underwent T-vNOTES hysterectomy, and 35 women underwent R-vNOTES hysterectomy without differences in operative time ($p = .37$), estimated blood loss ($p = .27$), length of hospital stay ($p = .06$), or reported postoperative pain levels at weeks 1, 2, and 3 after surgery ($p = .78$, $p = .36$, $p = .38$, respectively). A total of 6 patients underwent conversion in the T-vNOTES hysterectomy group compared with 0 in the R-vNOTES hysterectomy group; however, this was not statistically significantly different, and there were no conversions to laparotomy.
Conclusion: R-vNOTES hysterectomy is a feasible approach to surgery when compared with T-vNOTES hysterectomy and warrants further consideration as a skill set in a gynecologic surgeon's toolbox. Wristed instruments may allow surgeons who are inexperienced in single-site laparoscopy to adopt vNOTES more quickly as a new technique when performing hys-

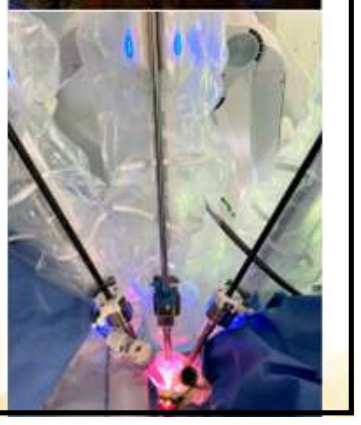

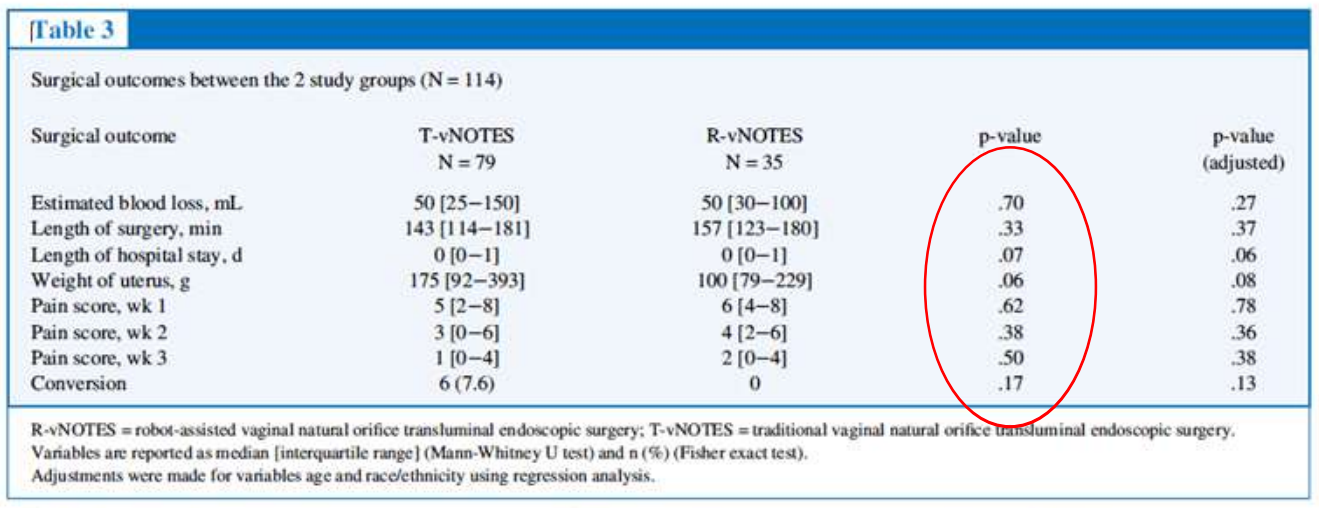

Table 3

Surgical outcomes between the 2 study groups (N = 114)

Surgical outcome	T-vNOTES N = 79	R-vNOTES N = 35	p-value	p-value (adjusted)
Estimated blood loss, mL	50 [25–150]	50 [30–100]	.70	.27
Length of surgery, min	143 [114–181]	157 [123–180]	.33	.37
Length of hospital stay, d	0 [0–1]	0 [0–1]	.07	.06
Weight of uterus, g	175 [92–393]	100 [79–229]	.06	.08
Pain score, wk 1	5 [2–8]	6 [4–8]	.62	.78
Pain score, wk 2	3 [0–6]	4 [2–6]	.38	.36
Pain score, wk 3	1 [0–4]	2 [0–4]	.50	.38
Conversion	6 (7.6)	0	.17	.13

R-vNOTES = robot-assisted vaginal natural orifice transluminal endoscopic surgery; T-vNOTES = traditional vaginal natural orifice transluminal endoscopic surgery.
Variables are reported as median [interquartile range] (Mann-Whitney U test) and n (%) (Fisher exact test).
Adjustments were made for variables age and race/ethnicity using regression analysis.



Received: 15 November 2021 | Revised: 26 February 2022 | Accepted: 28 February 2022

DOI: 10.1002/rcs.2385

ORIGINAL ARTICLE

The International Journal of Medical Robotics and Computer Assisted Surgery WILEY

Evaluation of the learning curve and safety outcomes in robotic assisted vaginal natural orifice transluminal endoscopic hysterectomy: A case series of 84 patients

Juan Liu[1,2] | Liping Tan[2] | Brooke Thigpen[1] | Tamisa Koythong[1] | Xingnan Zhou[2] | Qihuang Liu[2] | Qianqing Wang[3] | Xiaoming Guan[1]

[1] Department of Obstetrics and Gynaecology, Baylor College of Medicine, Houston, Texas, USA

[2] Department of Obstetrics and Gynaecology, The Third Affiliated Hospital of Guangzhou Medical University, Guangzhou, China

[3] Xinxiang Central Hospital, Xinxiang, China

Correspondence
Xiaoming Guan, Division of Minimally Invasive Gynecology Surgery, Baylor College of Medicine, 6651 Main Street, 10th Floor, Houston, TX 77030, USA.
Email: guanxiaoming@yahoo.com

Abstract

Background: To explore the learning curve and safety outcomes of robotic assisted transvaginal natural orifice transluminal endoscopic surgery (R-vNOTES) for hysterectomy in benign gynaecological diseases.

Methods: A retrospective chart review of all patients undergoing R-vNOTES hysterectomy for benign gynaecological disease from 2019 to 2021.

Setting: An academic tertiary care university hospital in Houston, TX, USA.

Results: 84 patients were identified that met the study requirements. The mean hysterectomy time was 77.27 ± 2.89 min. The median additional operation time was 63 (8–206) min. There were two conversions to robotic assisted single incision laparoscopy. Thirteen (15.48%) patients had an associated complication. Analysis of the learning curve suggests plateauing of hysterectomy time at approximately 10 cases and time for robot docking and port placement after 10–20 cases.

Conclusion: R-vNOTES is a safe and effective route for hysterectomy. For a surgeon with experience in laparoscopic single site surgery and abdominal robotic surgery, they need to perform 10 cases of R-vNOTES hysterectomy and 10–20 cases in port placement and robotic docking to achieve proficiency.

KEYWORDS
benign disease, hysterectomy, learning curve, robotic, transvaginal natural orifice transluminal endoscopic surgery (vNOTES)

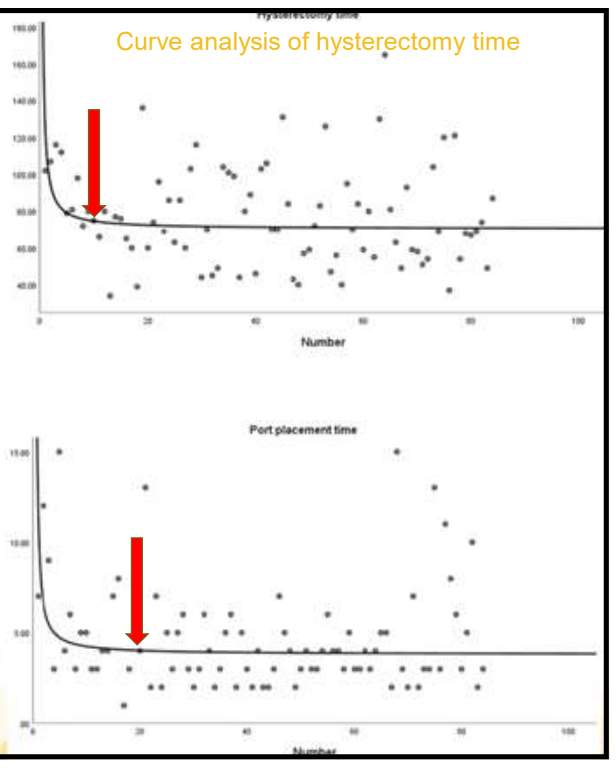

Curve analysis of hysterectomy time

Transvaginal NOTES Benefits

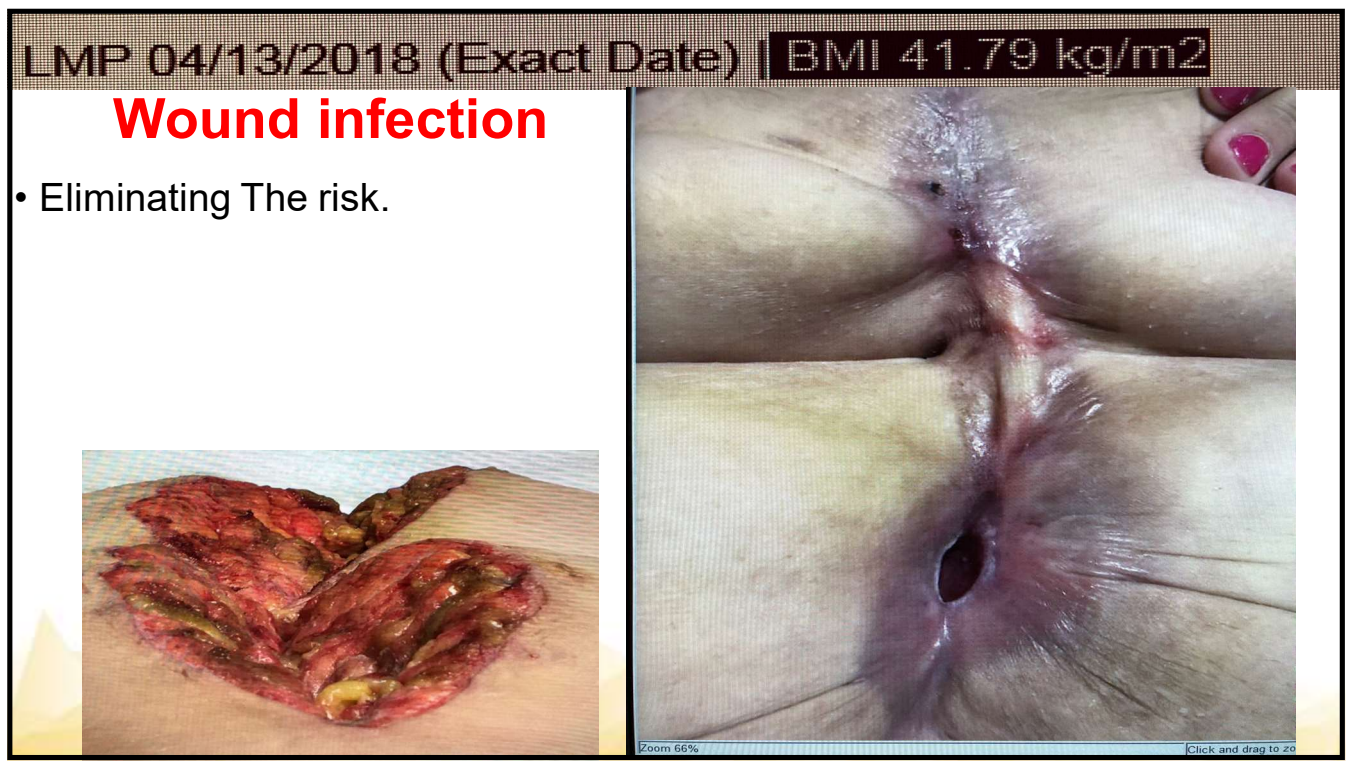

LMP 04/13/2018 (Exact Date) | BMI 41.79 kg/m2

Wound infection

- Eliminating The risk.

Zoom 66%
Click and drag to zo

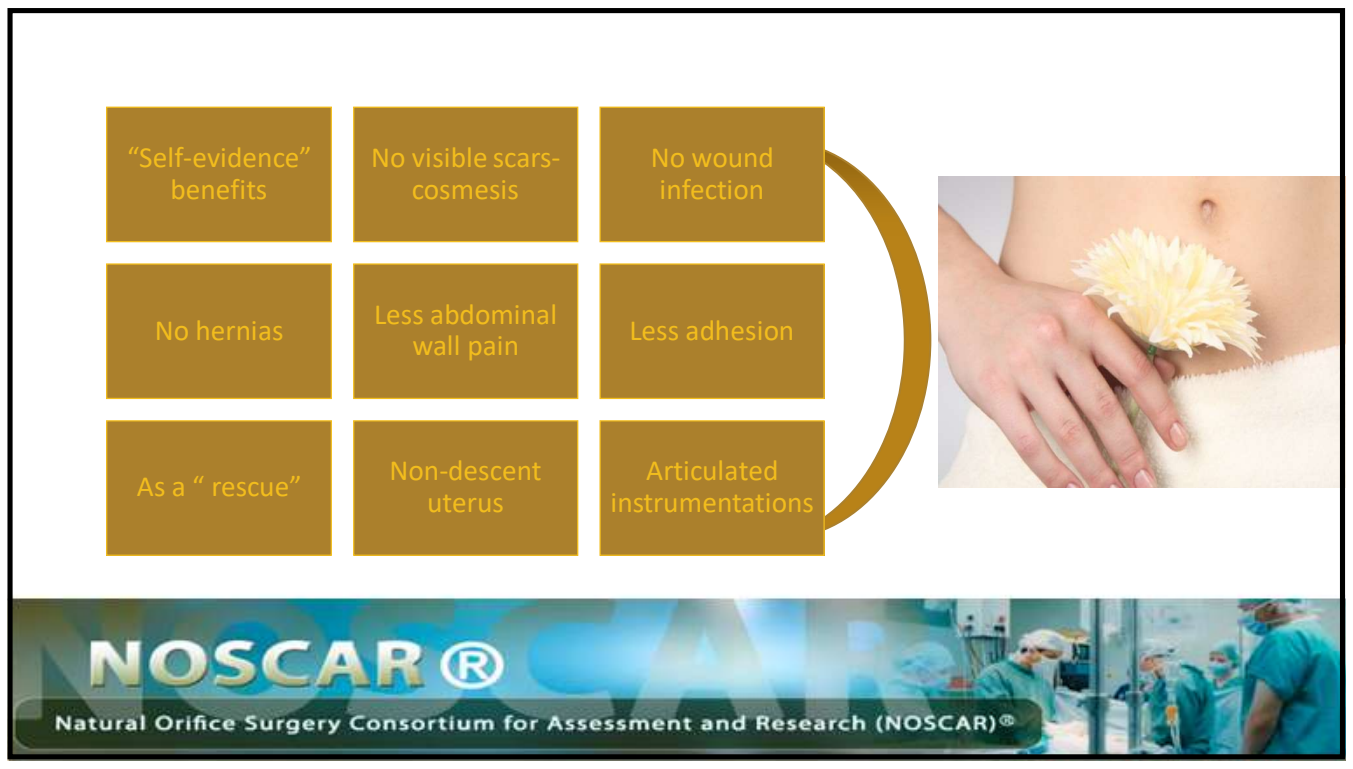

"Self-evidence" benefits

No visible scars-cosmesis

No wound infection

No hernias

Less abdominal wall pain

Less adhesion

As a " rescue"

Non-descent uterus

Articulated instrumentations

NOSCAR®

Natural Orifice Surgery Consortium for Assessment and Research (NOSCAR)®

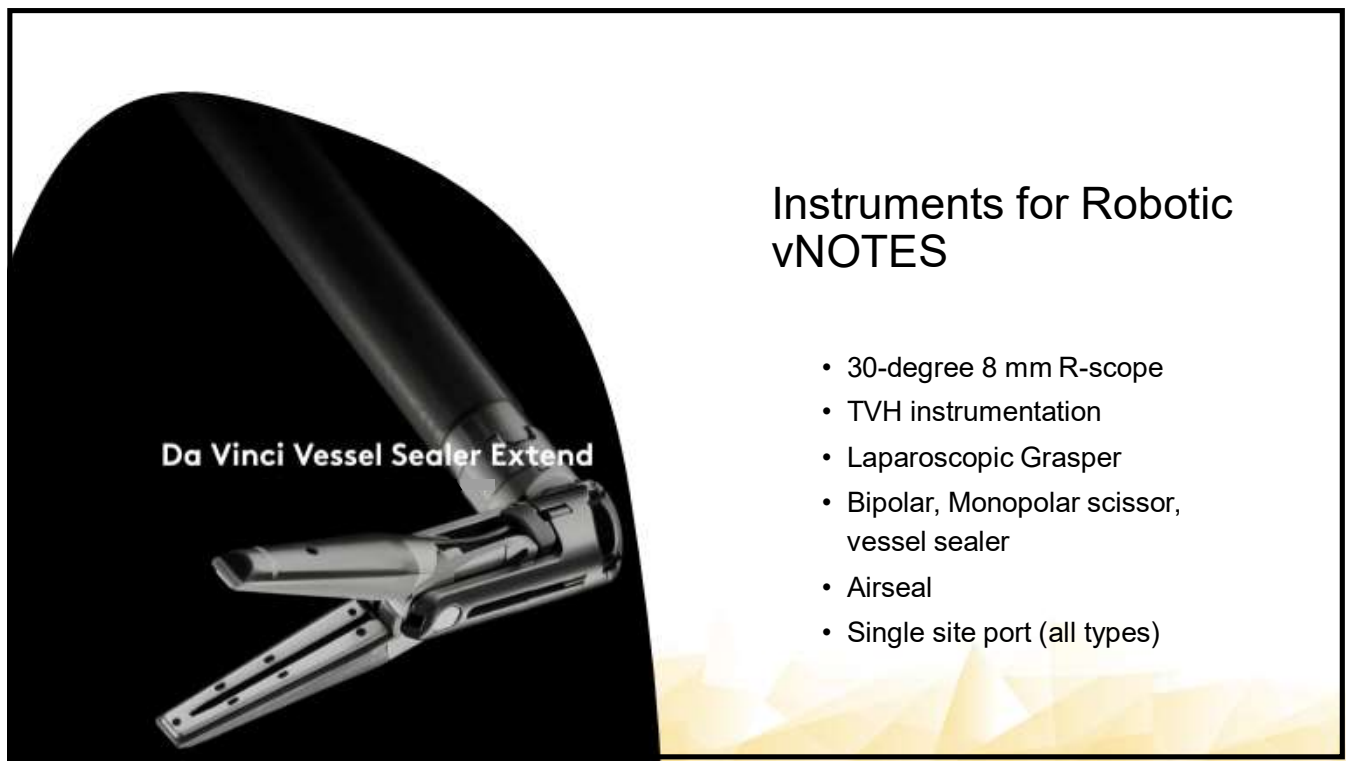

Da Vinci Vessel Sealer Extend

Instruments for Robotic vNOTES

- 30-degree 8 mm R-scope
- TVH instrumentation
- Laparoscopic Grasper
- Bipolar, Monopolar scissor, vessel sealer
- Airseal
- Single site port (all types)

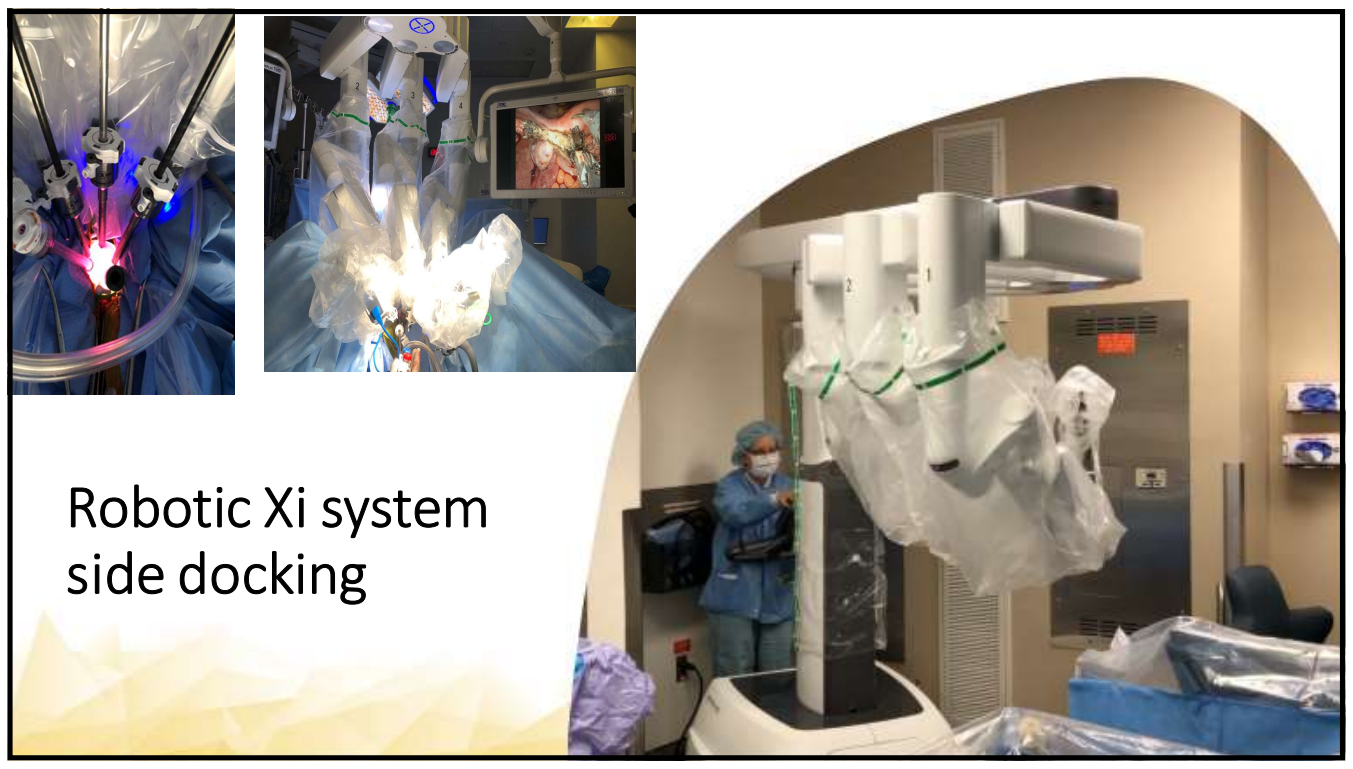

Robotic Xi system side docking

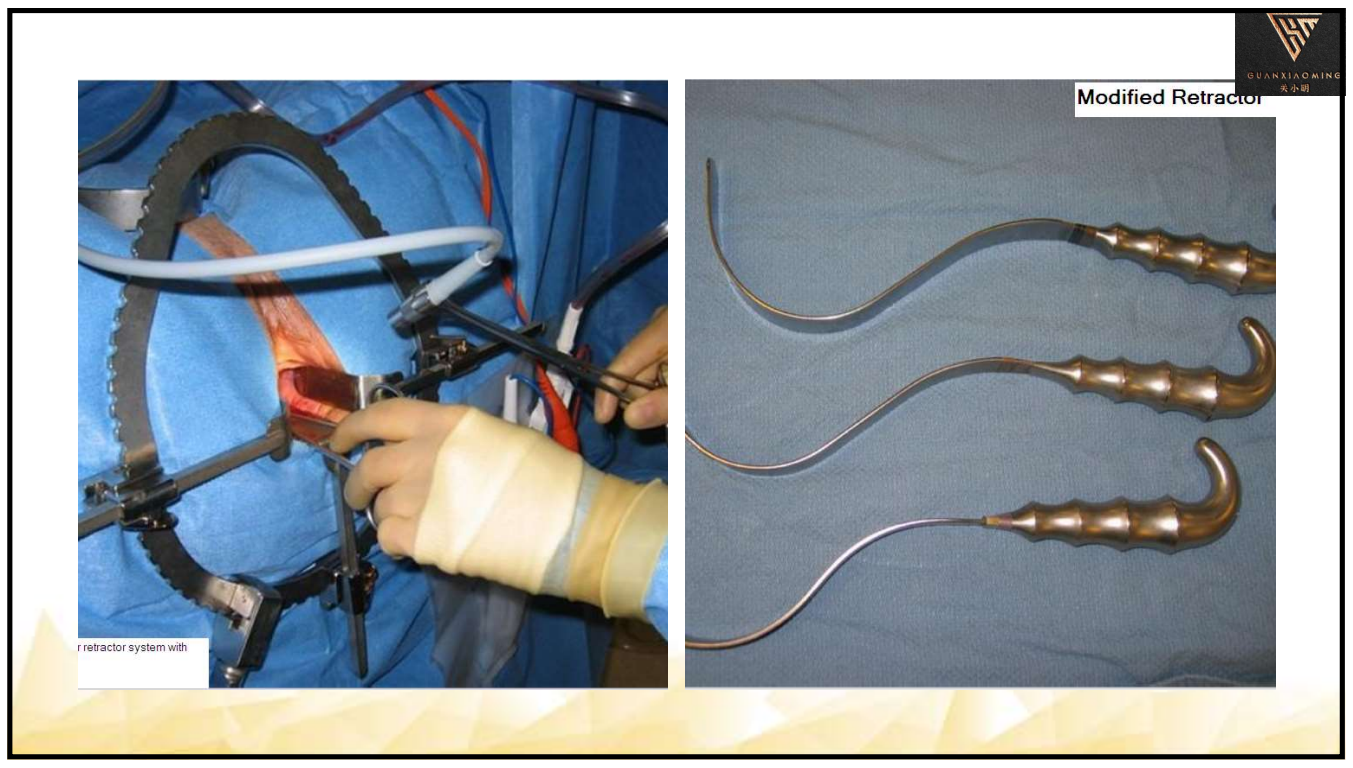

r retractor system with
Modified Retractor

Packed around the speciment

Video will be played during lecture

Video will be played during lecture

WAVE sign for vNOTE anterior coloptomy-Thailand

Video will be played during lecture

Video will be played during lecture

What Have been done in Robotic VNOTES?

- Hysterectomy
- Adnexal surgeries
- Myomectomy
- High uterosacral ligament suspension
- Sacrocolpopexy
- Endometriosis resection
- Cancer surgery (not yet)

2.335 kg=5.15 lbs fibroi

Video will be played during lecture

Video will be played during lecture

Video will be played during lecture

Video will be played during lecture

References

- Su H, Yen CF, Wu KY, Han CM, Lee CL. Hysterectomy via transvaginal natural orifice transluminal endoscopic surgery (NOTES): feasibility of an innovative approach. *Taiwan J Obstet Gynecol*. 2012;51(2):217-221. doi:10.1016/j.tjog.2012.04.009
- 王卡娜,陈思敬,郑莹. 郑氏4C悬吊法在经脐单孔腹腔镜妇科恶性肿瘤手术中的应用[J]. 中华腔镜外科杂志（电子版）,2021,14(1):5-9.
- Zhenkun Guan, Samit D. Soni, Jerry Zhou, Sowmya Sunkara, Xiaoming Guan. Cystoscopic-Guided Robotic Resection of Bladder Trigone Endometriosis Nodule with Ureteral Preservation. J Minim Invasive Gynecol. 2022 May 23:S1553-4650(22)00204-7. doi: 10.1016/j.jmig.2022.05.012. Epub ahead of print. PMID: 35618233
- Brooke Thigpen, Tamisa Koythong, Xiaoming Guan, Robotic-Assisted Laparoscopic Ureterolysis for Deep Infiltrating Endometriosis Using Indocyanine Green Under Near-Infrared Fluorescence, Journal of Minimally Invasive Gynecology, 2022, ISSN 1553-4650. https://doi.org/10.1016/j.jmig.2022.01.018.
- Tamisa Koythong, Brooke Thigpen, Sowmya Sunkara, Hadi Erfani, Stephanie Delgado, Xiaoming Guan. Surgical outcomes of hysterectomy via robotic assisted versus traditional transvaginal natural orifice transluminal endoscopic surgery. J Minim Invasive Gynecol. 2021 May 22:S1553-4650(21)00236-3. doi: 10.1016/j.jmig.2021.05.014. Epub ahead of print. PMID: 34033911.
- Xiaoming Guan, Zhenkun Guan, Tamisa Koythong, Juan Liu. Robotic Assisted Transvaginal Single-Site Sacrocolpopexy for Pelvic Organ Prolapse. J Minim Invasive Gynecol. November 26, 2020 DOI:https://doi.org/10.1016/j.jmig.2020.11.018
- Chen S, Zheng Y, Tong L, Zhao X, Chen L, Wang Y. Laparoendoscopic Single-site Radical Hysterectomy with Vaginal Closure and without Uterine Manipulator for FIGO IB1 Cervical Cancer. J Minim Invasive Gynecol. 2020 Nov-Dec;27(7):1471-1472. doi: 10.1016/j.jmig.2020.01.003. Epub 2020 Jan 9. PMID: 31926301.
- Lee CL, Wu KY, Su H, Han CM, Huang CY, Yen CF. Robot-assisted natural orifice transluminal endoscopic surgery for hysterectomy. *Taiwan J Obstet Gynecol*. 2015;54(6):761-765. doi:10.1016/j.tjog.2015.08.023
- Baekelandt JF, De Mulder PA, Le Roy I, et al. Transvaginal natural orifice transluminal endoscopic surgery (vNOTES) adnexectomy for benign pathology compared with laparoscopic excision (NOTABLE): a protocol for a randomised controlled trial. *BMJ Open*. 2018;8(1):e018059. Published 2018 Jan 10. doi:10.1136/bmjopen-2017-018059
- Shadi Rezai, Richard A. Giovane, Savannah Nicole Johnson, Cassandra Henderson, Juan Liu, **Xiaoming Guan**. Robotic Natural Orifice Transluminal Endoscopic Surgery (R-NOTES) in Gynecologic Surgeries, A case report and Review of Literature. Obstet Gynecol Int J. 2019.
- Koythong T, Thigpen B, Sunkara S, Erfani H, Delgado S, Guan X. Surgical Outcomes of Hysterectomy via Robot-assisted versus Traditional Transvaginal Natural Orifice Transluminal Endoscopic Surgery. J Minim Invasive Gynecol. 2021 May 24:S1553-4650(21)00236-3. doi: 10.1016/j.jmig.2021.05.014. Epub ahead of print. PMID: 34033911.
- Guan X, Guan Z, Koythong T, Liu J. Robot-assisted Transvaginal Single-site Sacrocolpopexy for Pelvic Organ Prolapse. J Minim Invasive Gynecol. 2021 Jun;28(6):1141. doi: 10.1016/j.jmig.2020.11.018. Epub 2020 Nov 26. PMID: 33249270.
- Guan X, Guan Z, Koythong T, Liu J, Delgado S, Wang Q. Integration of a Robotic Platform for Sacrocolpopexy in Transvaginal Natural Orifice Transluminal Endoscopic Surgery: A Novel Surgical Technique. Urology. 2021 Aug;154:109-114. doi: 10.1016/j.urology.2021.03.015. Epub 2021 Mar 26. PMID: 33775785.
- Zhang Y, Delgado S, Liu J, Guan Z, Guan X. Robot-assisted Transvaginal Natural Orifice Transluminal Endoscopic Surgery for Management of Endometriosis: A Pilot Study of 33 Cases. J Minim Invasive Gynecol. 2021 Jun 15:S1553-4650(21)00283-1. doi: 10.1016/j.jmig.2021.06.004. Epub ahead of print. PMID: 34144208.
- Guan X, Welch JR, Wu G. Robotic Transvaginal Natural Orifice Transluminal Endoscopic Surgery for Resection of Parametrial and Bowel Deeply Infiltrated Endometriosis. J Minim Invasive Gynecol. 2021 Dec 3:S1553-4650(21)01288-7. doi: 10.1016/j.jmig.2021.11.020. Epub ahead of print. PMID: 34871771.
- Sowmya Sunkara, Xiaoming Guan. Robotic vaginal natural orifice transluminal endoscopic surgery for myomectomy. Fertil Steril. 2022 Jun 9:S0015-0282(22)00312-0. doi: 10.1016/j.fertnstert.2022.05.009. Epub ahead of print. PMID: 35691722.
- **Arnold Advincula, Tamisa Koythong, Juan Liu, Xiaoming Guan. Minimally Invasive Gynecologic Surgery update: vNOTES Hysterectomy. OBG Management,**

CULTURAL AND LINGUISTIC COMPETENCY & IMPLICIT BIAS

The California Medical Association (CMA) announced new standards for Cultural Linguistic Competency and Implicit Bias in CME. The goal of the standards is to support the role of accredited CME in advancing diversity, health equity, and inclusion in healthcare. These standards are relevant to ACCME-accredited, CMA-accredited, and jointly accredited providers located in California. AAGL is ACCME-accredited and headquartered in California.

CMA developed the standards in response to California legislation (Business and Professions (B&P) Code Section 2190.1), which directs CMA to draft a set of standards for the inclusion of cultural and linguistic competency (CLC) and implicit bias (IB) in accredited CME.

The standards are intended to support CME providers in meeting the expectations of the legislation. CME provider organizations physically located in California and accredited by CMA CME or ACCME, as well as jointly accredited providers whose target audience includes physicians, are expected to meet these expectations beginning January 1, 2022. AAGL has been proactively adopting processes that meet and often exceed the required expectations of the legislation.

CMA CME offers a variety of resources and tools to help providers meet the standards and successfully incorporate CLC & IB into their CME activities, including FAQ, definitions, a planning worksheet, and best practices. These resources are available on the CLC and IB standards page on the CMA website.

Important Definitions:

Cultural and Linguistic Competency (CLC) – The ability and readiness of health care providers and organizations to humbly and respectfully demonstrate, effectively communicate, and tailor delivery of care to patients with diverse values, beliefs, identities and behaviors, in order to meet social, cultural and linguistic needs as they relate to patient health.

Implicit Bias (IB) – The attitudes, stereotypes and feelings, either positive or negative, that affect our understanding, actions and decisions without conscious knowledge or control. Implicit bias is a universal phenomenon. When negative, implicit bias often contributes to unequal treatment and disparities in diagnosis, treatment decisions, levels of care and health care outcomes of people based on race, ethnicity, gender identity, sexual orientation, age, disability and other characteristics.

Diversity – Having many different forms, types or ideas; showing variety. Demographic diversity can mean a group composed of people of different genders, races/ethnicities, cultures, religions, physical abilities, sexual orientations or preferences, ages, etc.

Direct links to AB1195 (CLC), AB241 (IB), and the B&P Code 2190.1:
Bill Text – AB-1195 Continuing education: cultural and linguistic competency.
Bill Text – AB-241 Implicit bias: continuing education: requirements.
Business and Professions (B&P) Code Section 2190.1

CLC & IB Online Resources:
Diversity-Wheel-as-used-at-Johns-Hopkins-University-12.png (850×839) (researchgate.net)
Cultural Competence In Health and Human Services | NPIN (cdc.gov)
Cultural Competency – The Office of Minority Health (hhs.gov)
Implicit Bias, Microaggressions, and Stereotypes Resources | NEA
Unconscious Bias Resources | diversity.ucsf.edu
Act, Communicating, Implicit Bias (racialequitytools.org)
https://kirwaninstitute.osu.edu/implicit-bias-training
https://www.uptodate.com/contents/racial-and-ethnic-disparities-in-obstetric-and-gynecologic-care-and-role-of-implicitbiases
https://www.contemporaryobgyn.net/view/overcoming-racism-and-unconscious-bias-in-ob-gyn
https://pubmed.ncbi.nlm.nih.gov/34016820/